

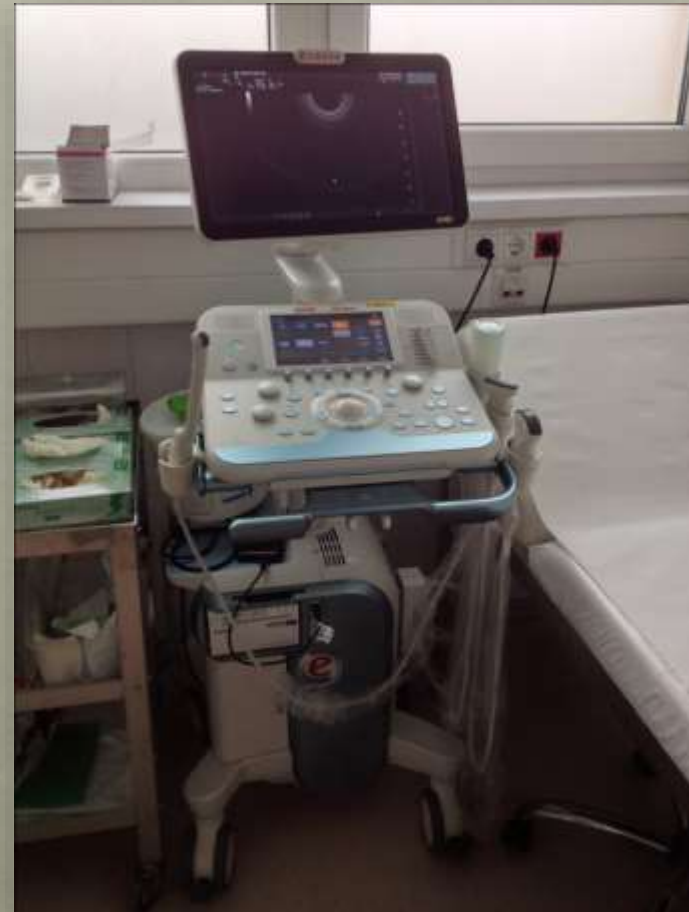ULTRAHANG DIAGNOSZTIKA AZ UROLÓGIÁBAN



Dr. Kocsis István Tamás

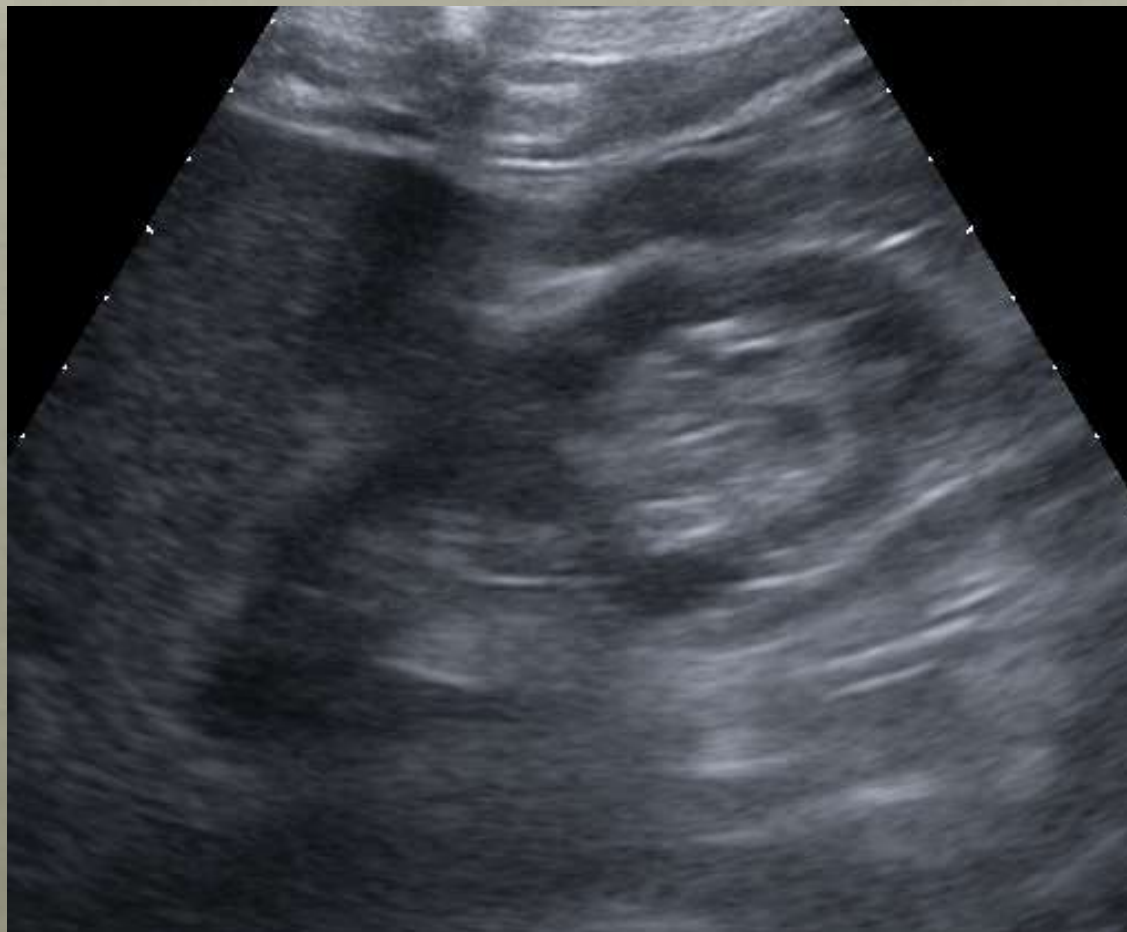„Szegedi Úti Akadémia 2016”

A GÉP

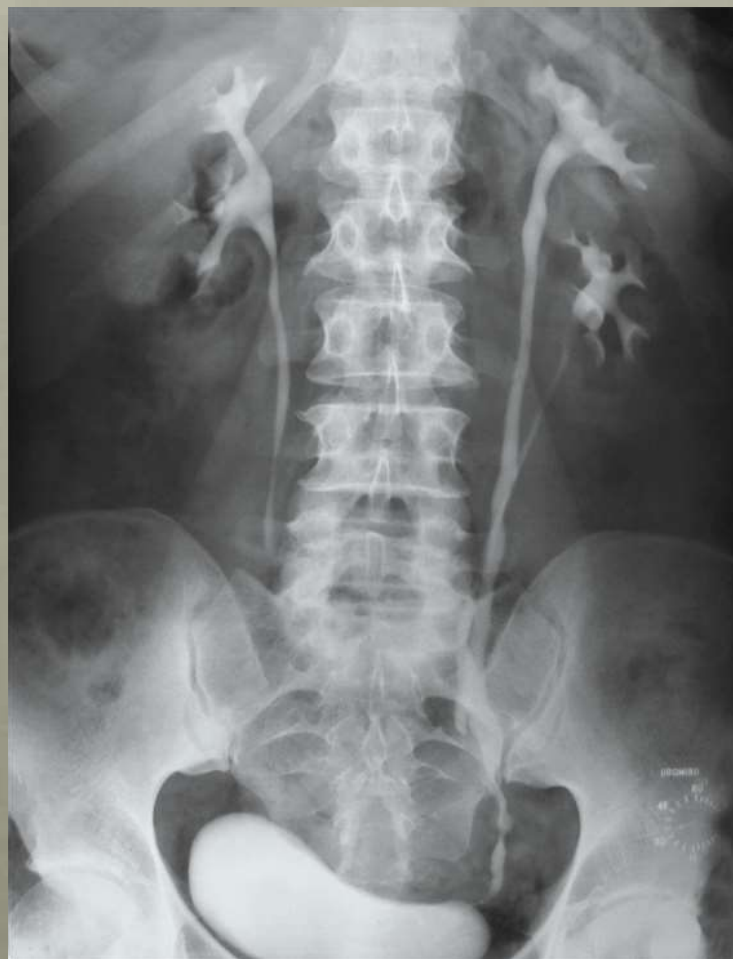

1987 - 2016

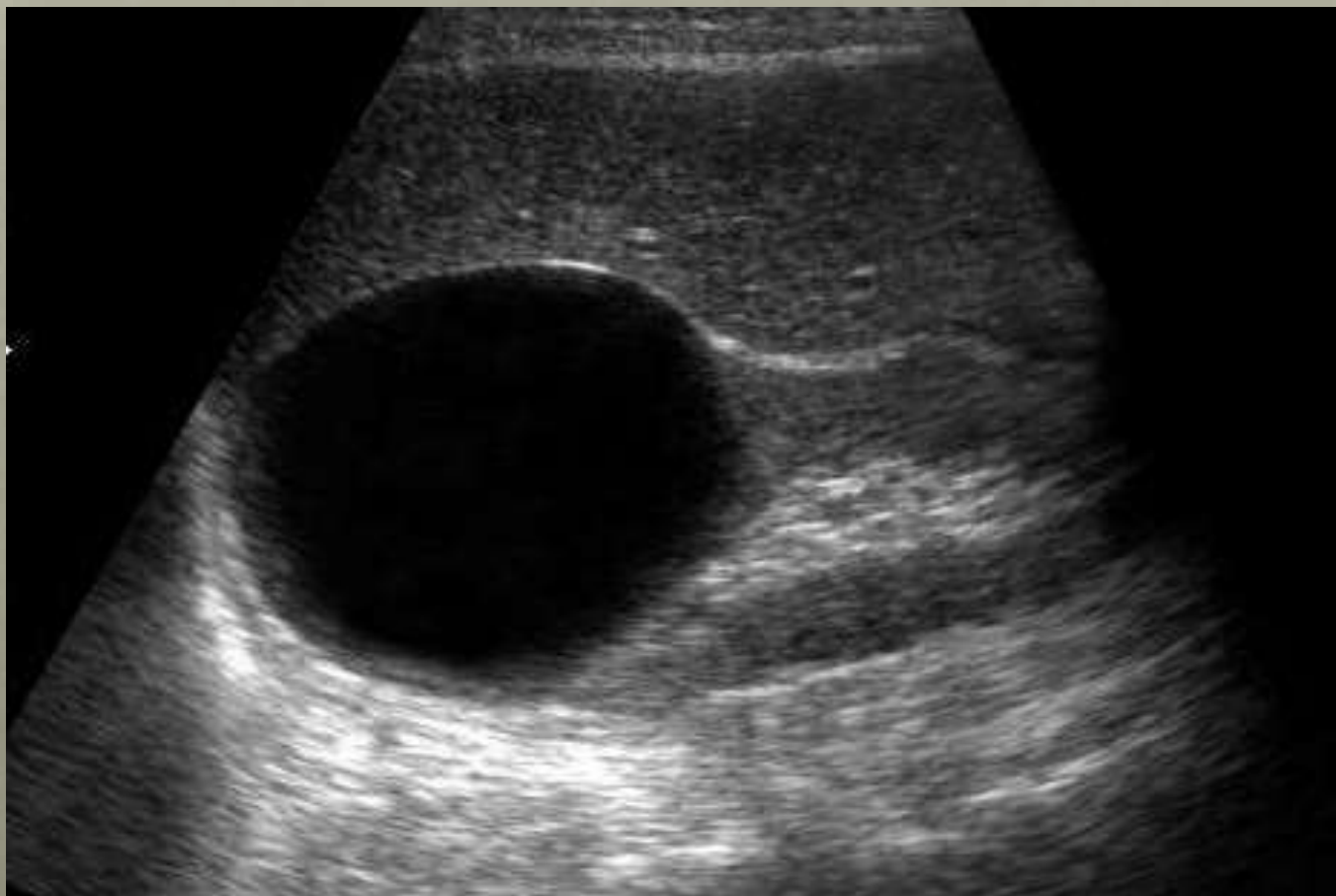
A VESE



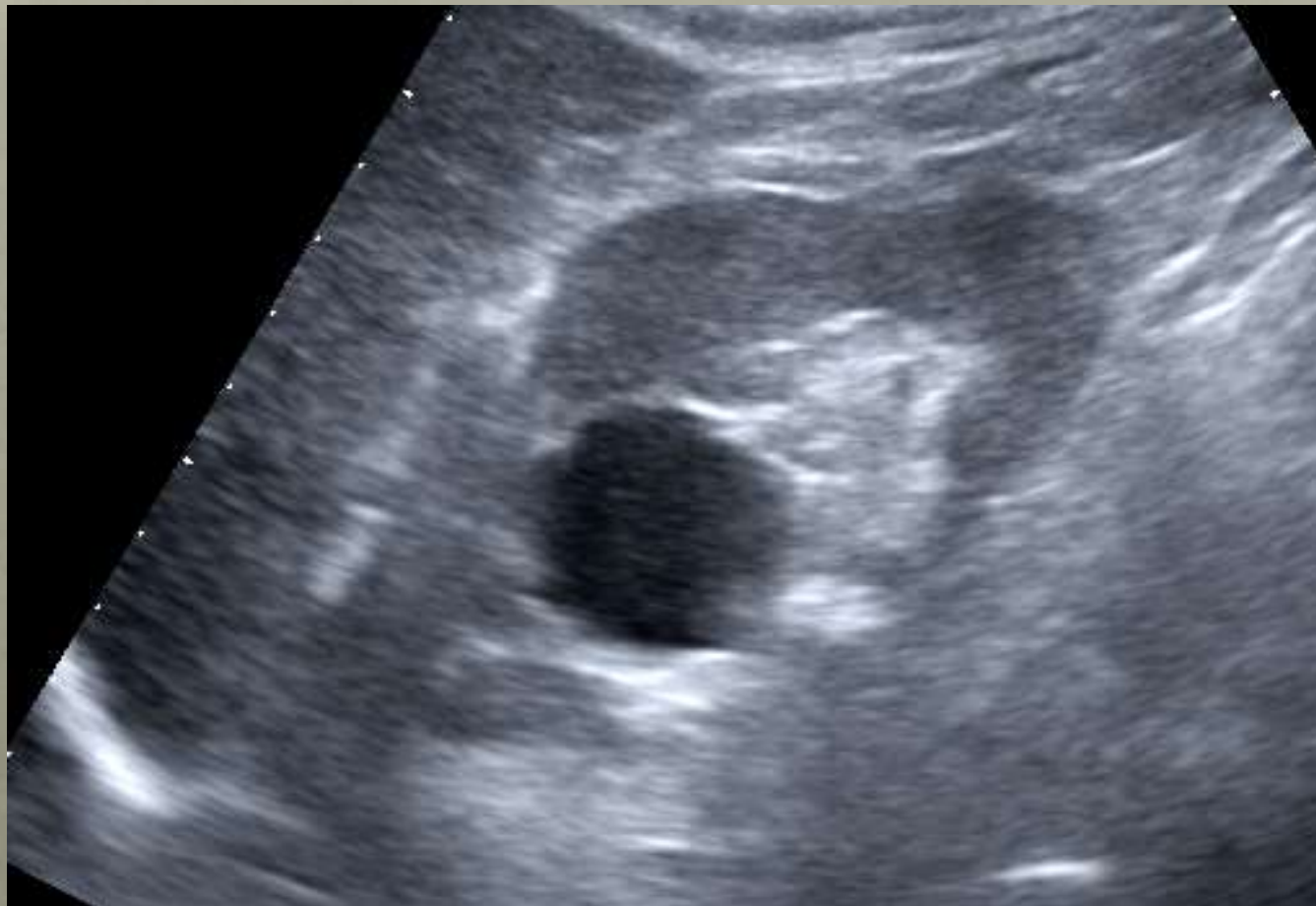
A VESE



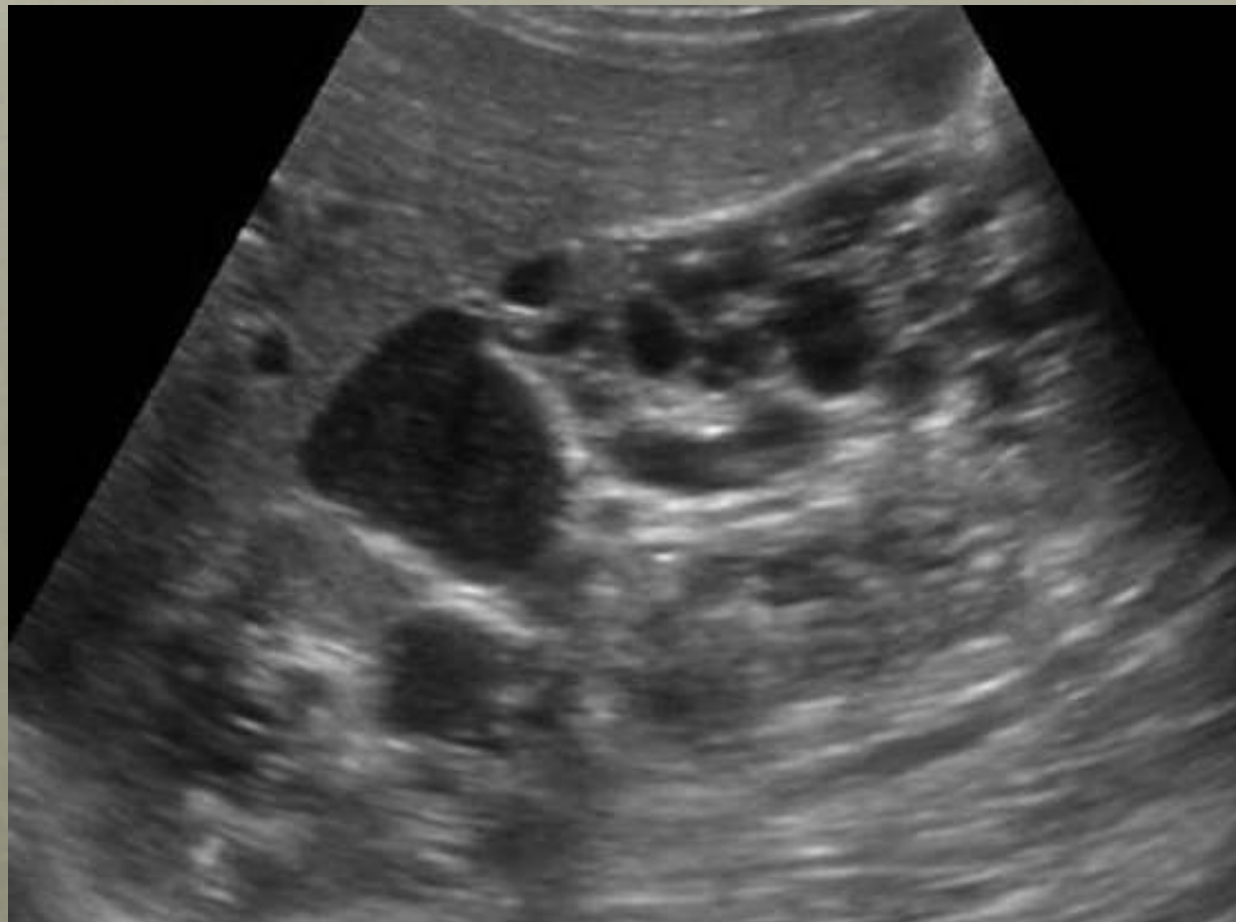
A VESE



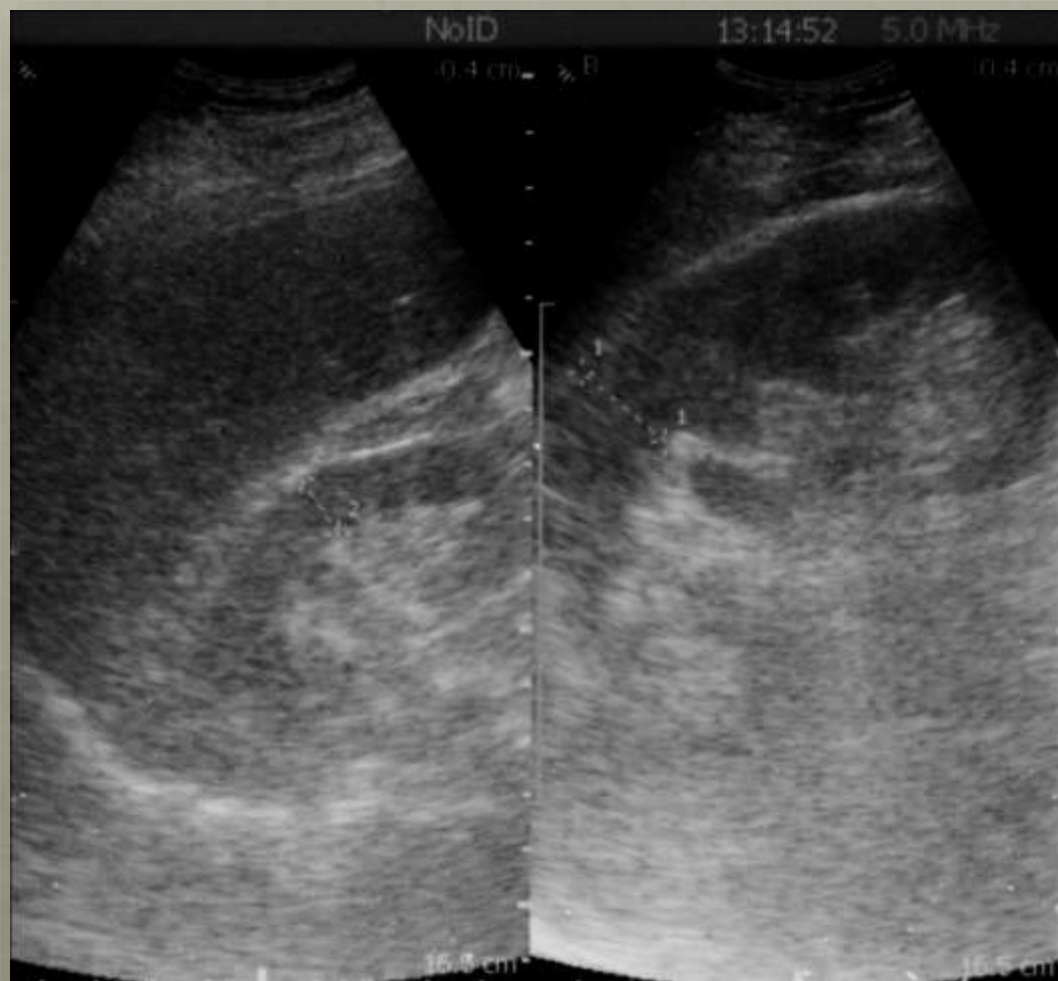A VESE



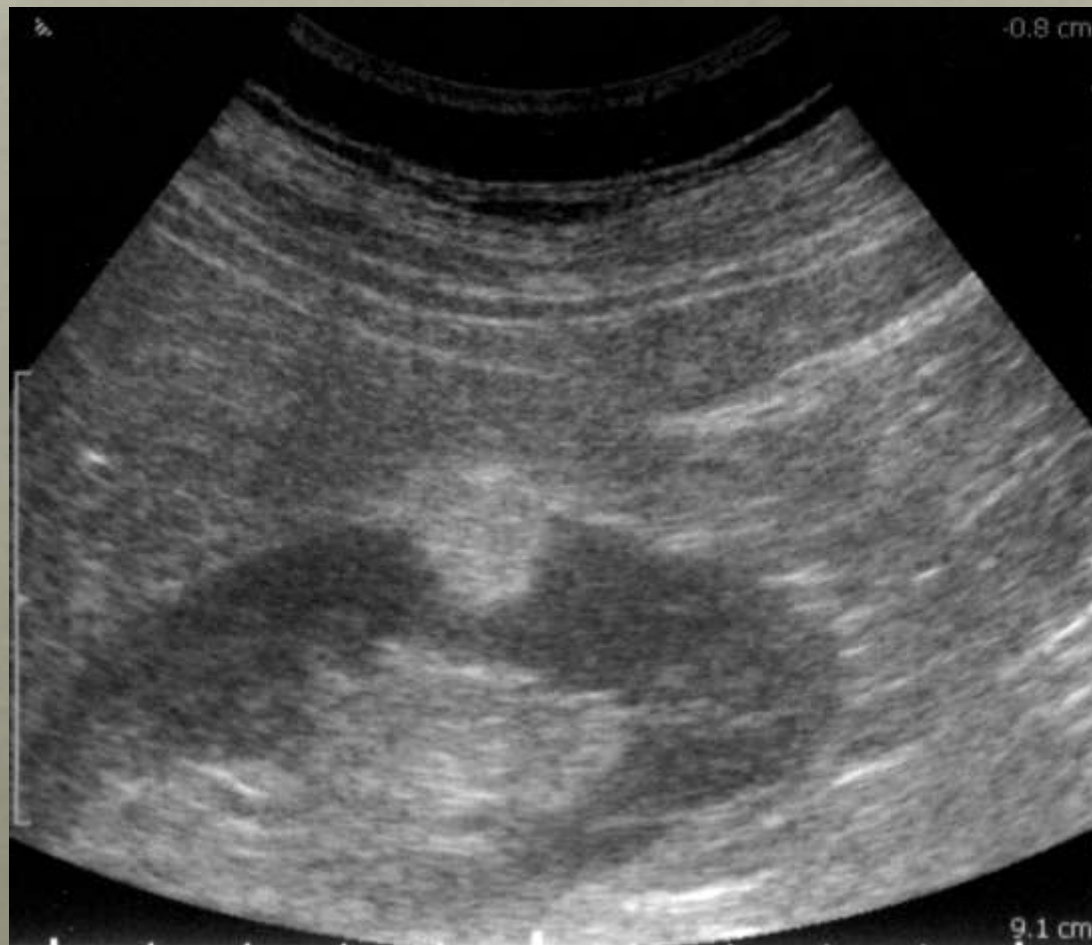A VESE



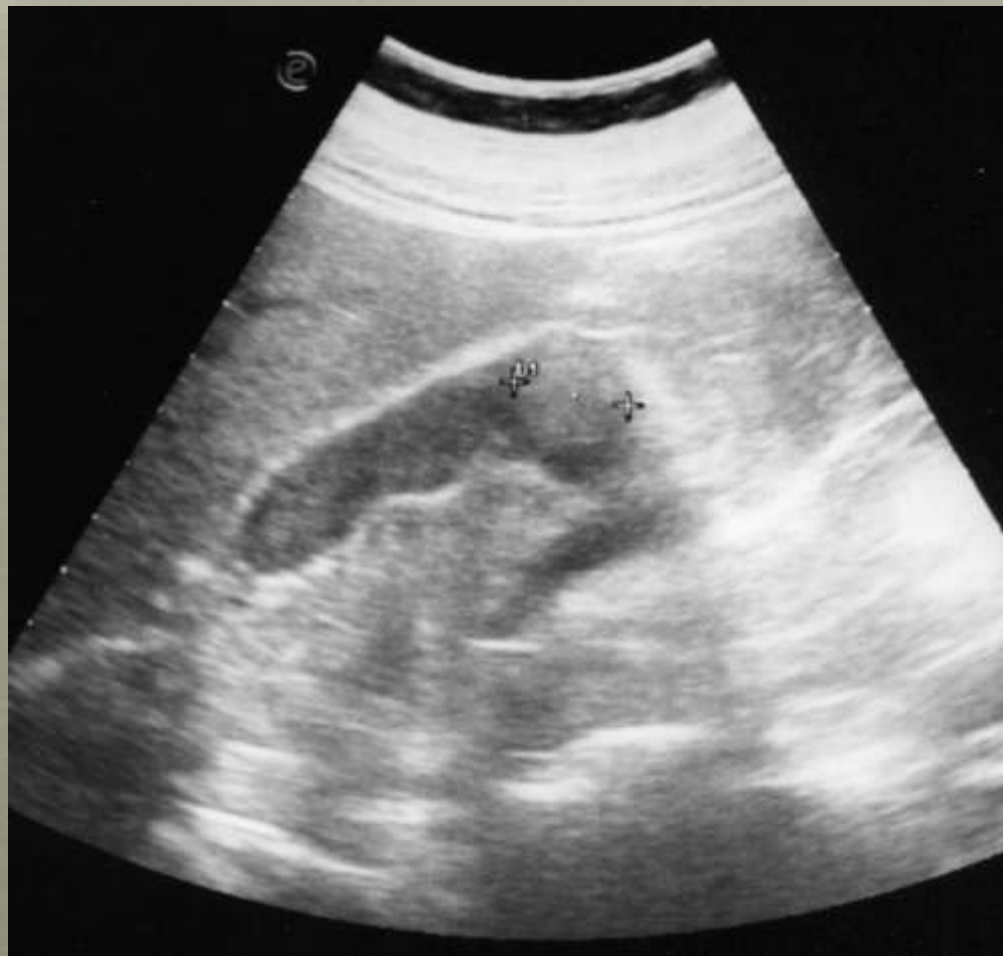A VESE



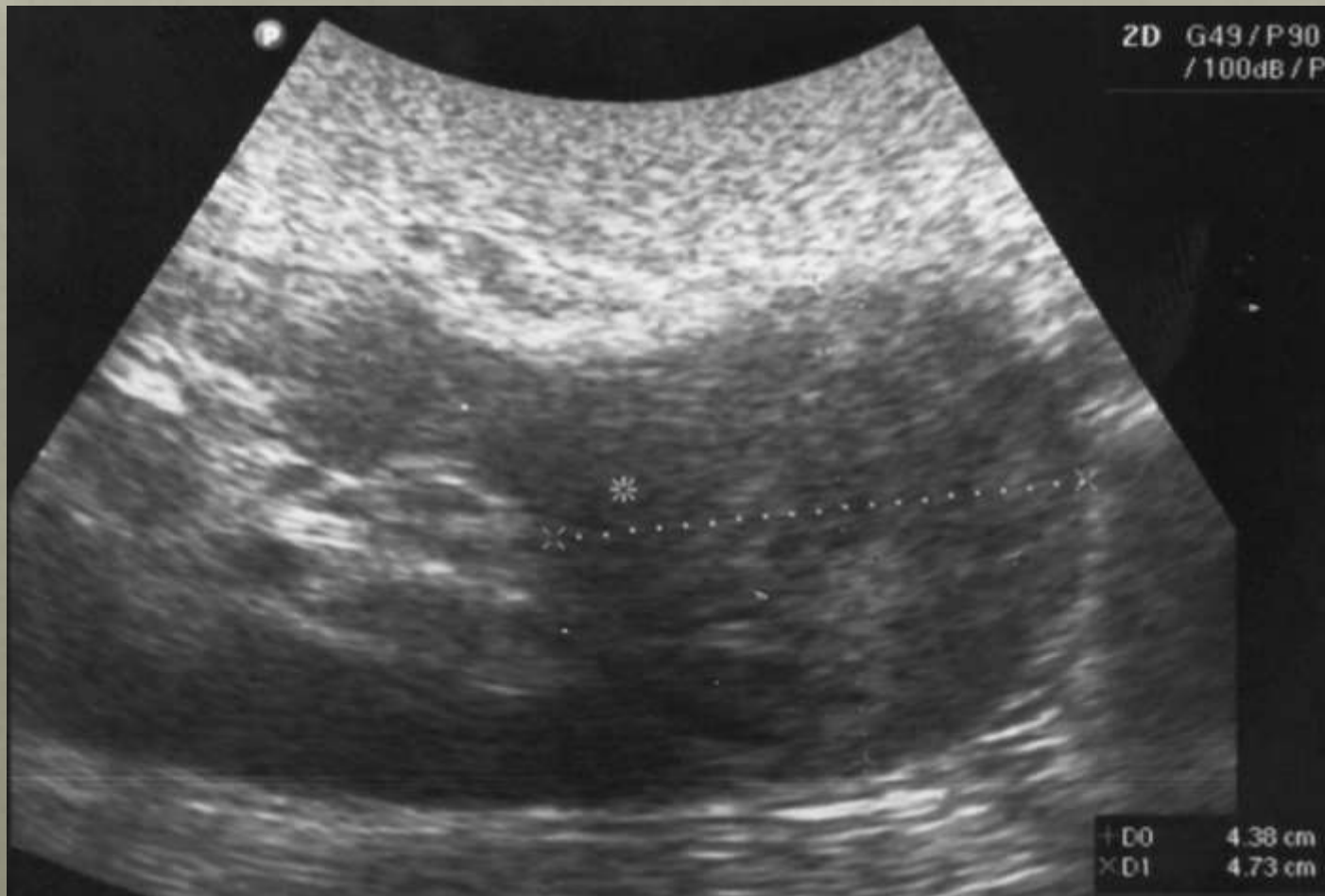
A VESE



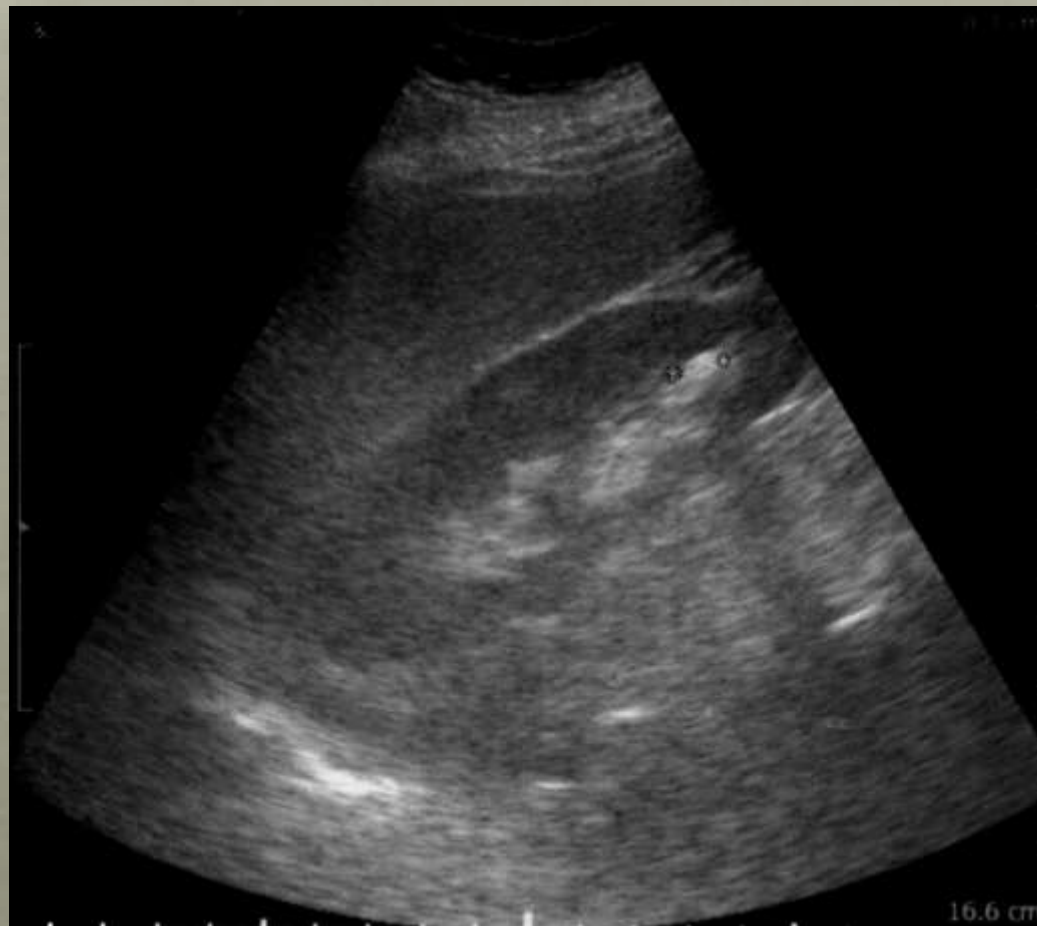A VESE



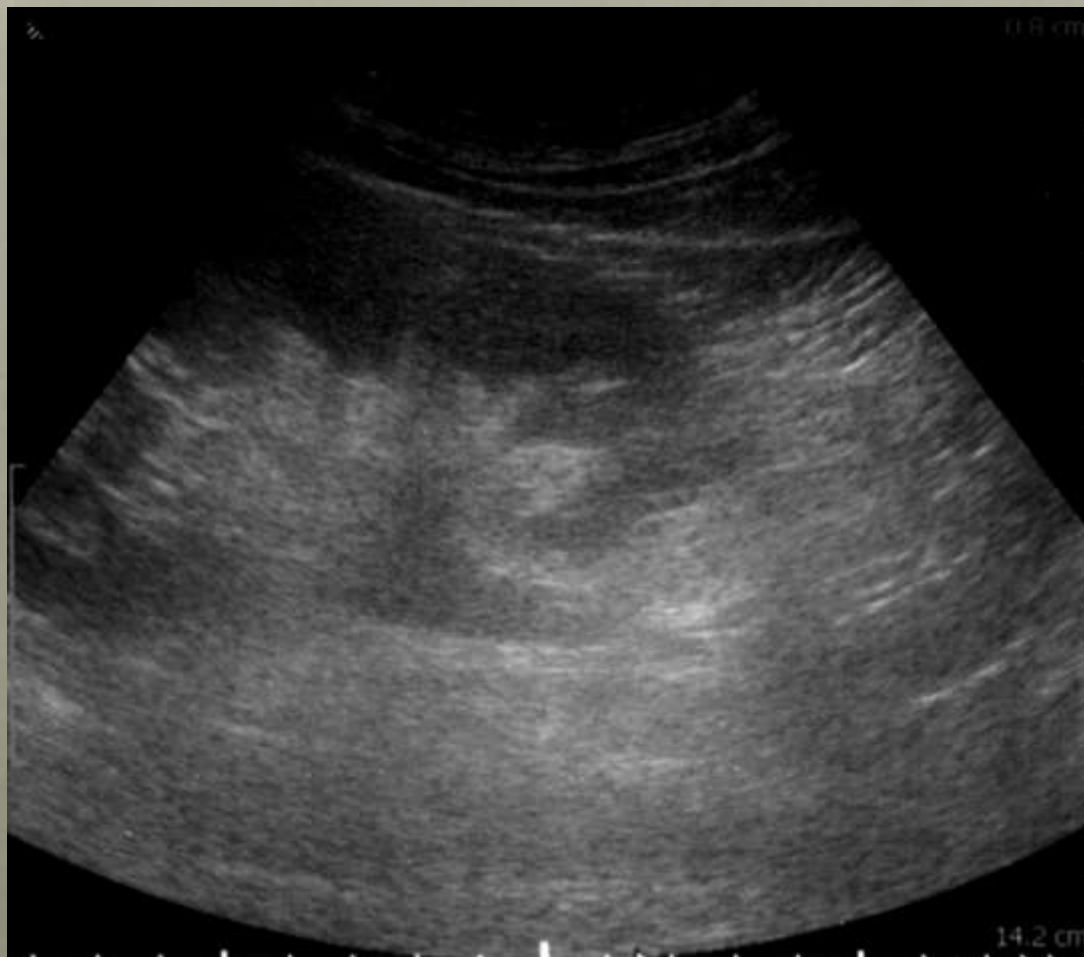A VESE



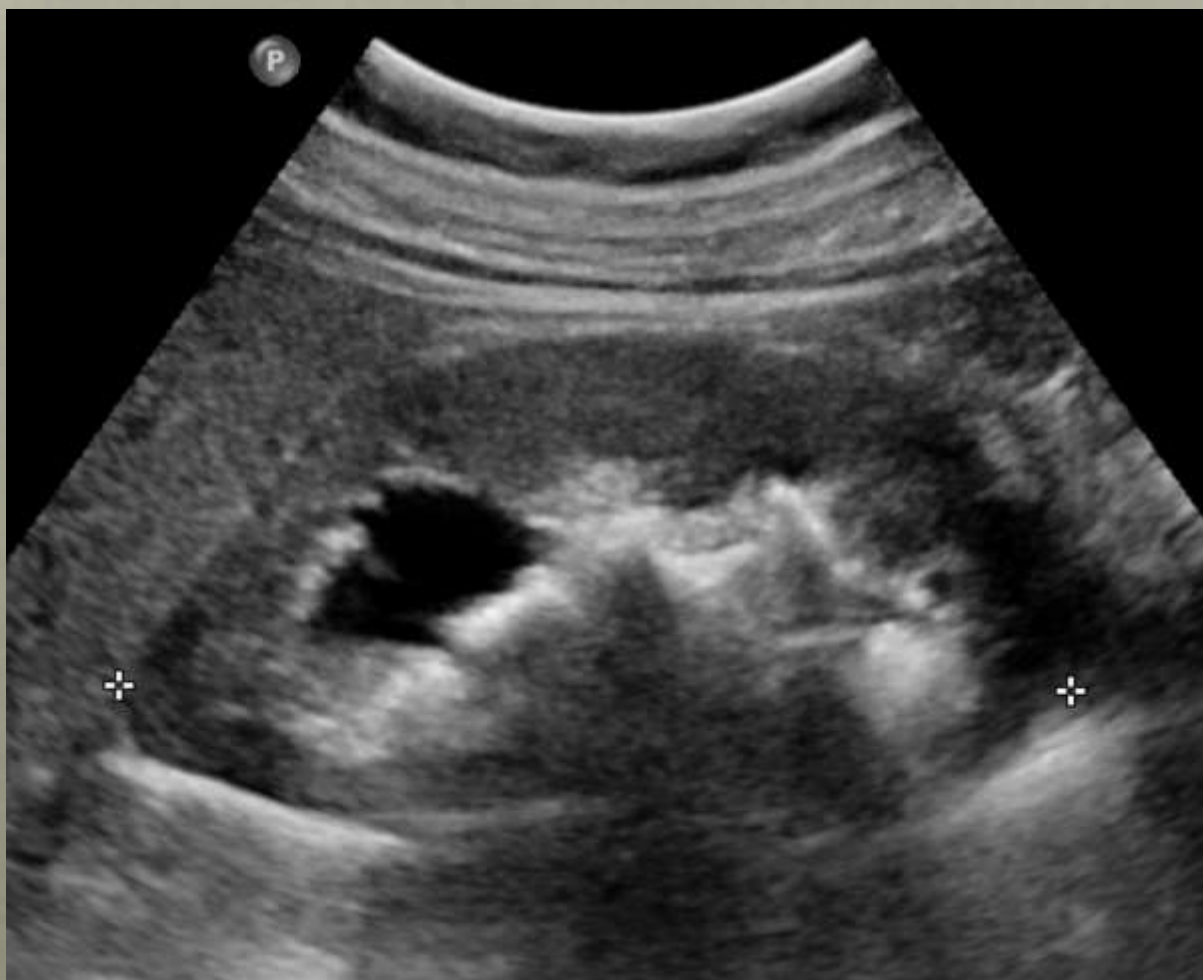A VESE



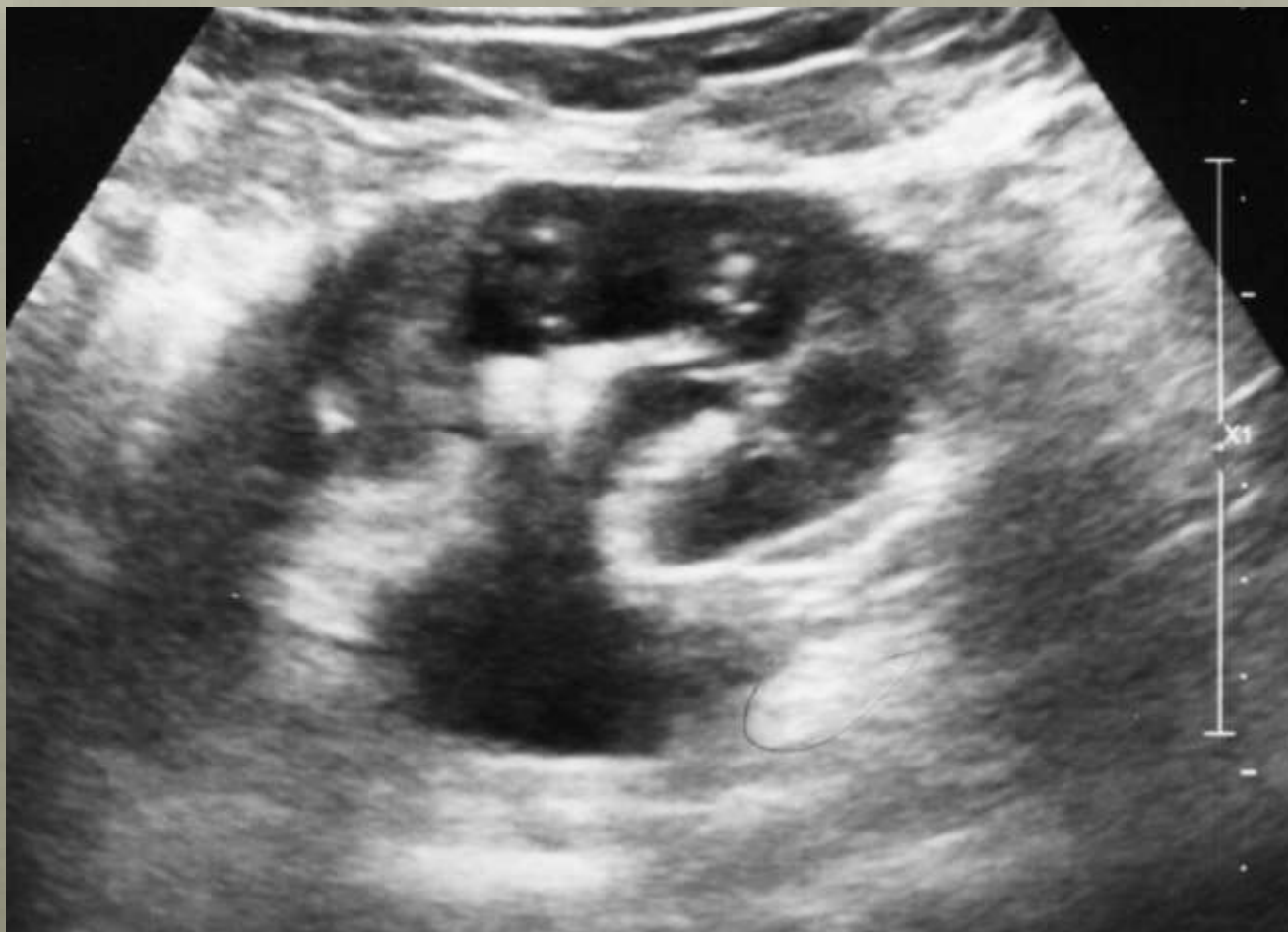A VESE



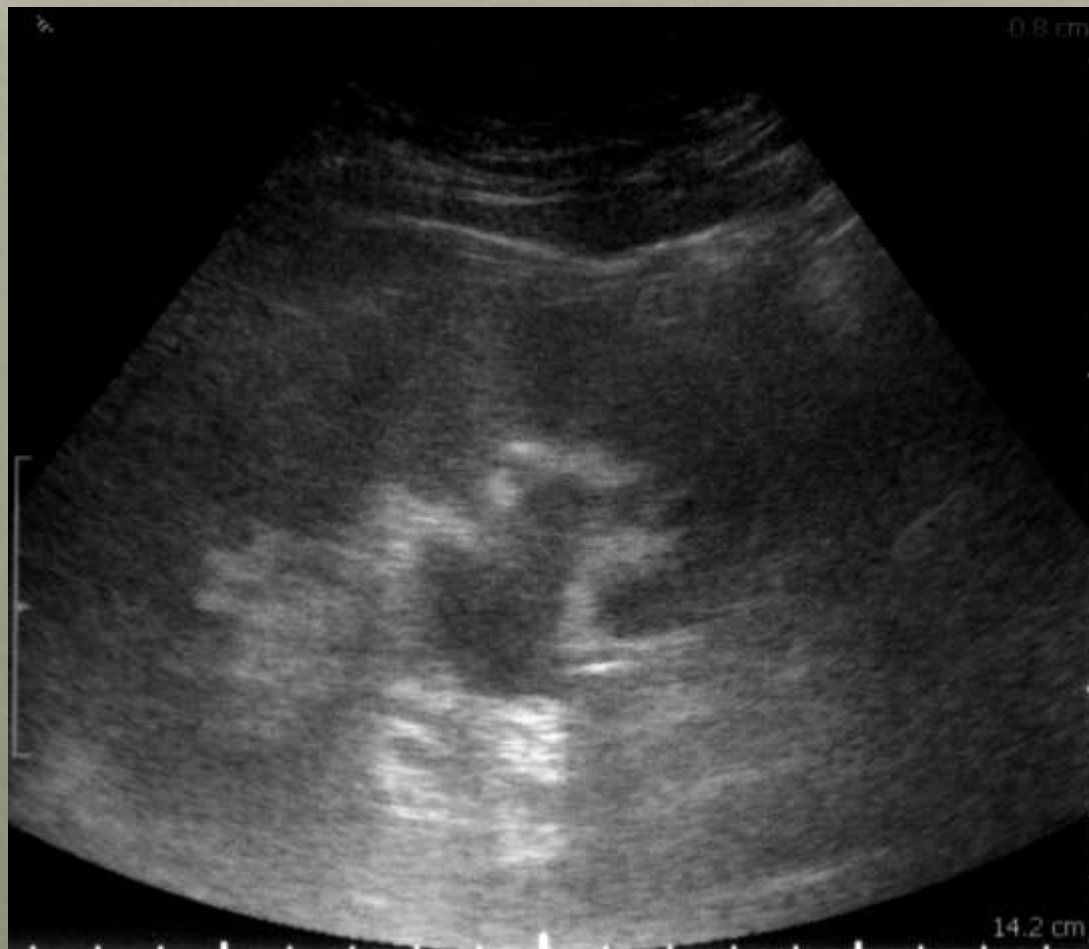A VESE



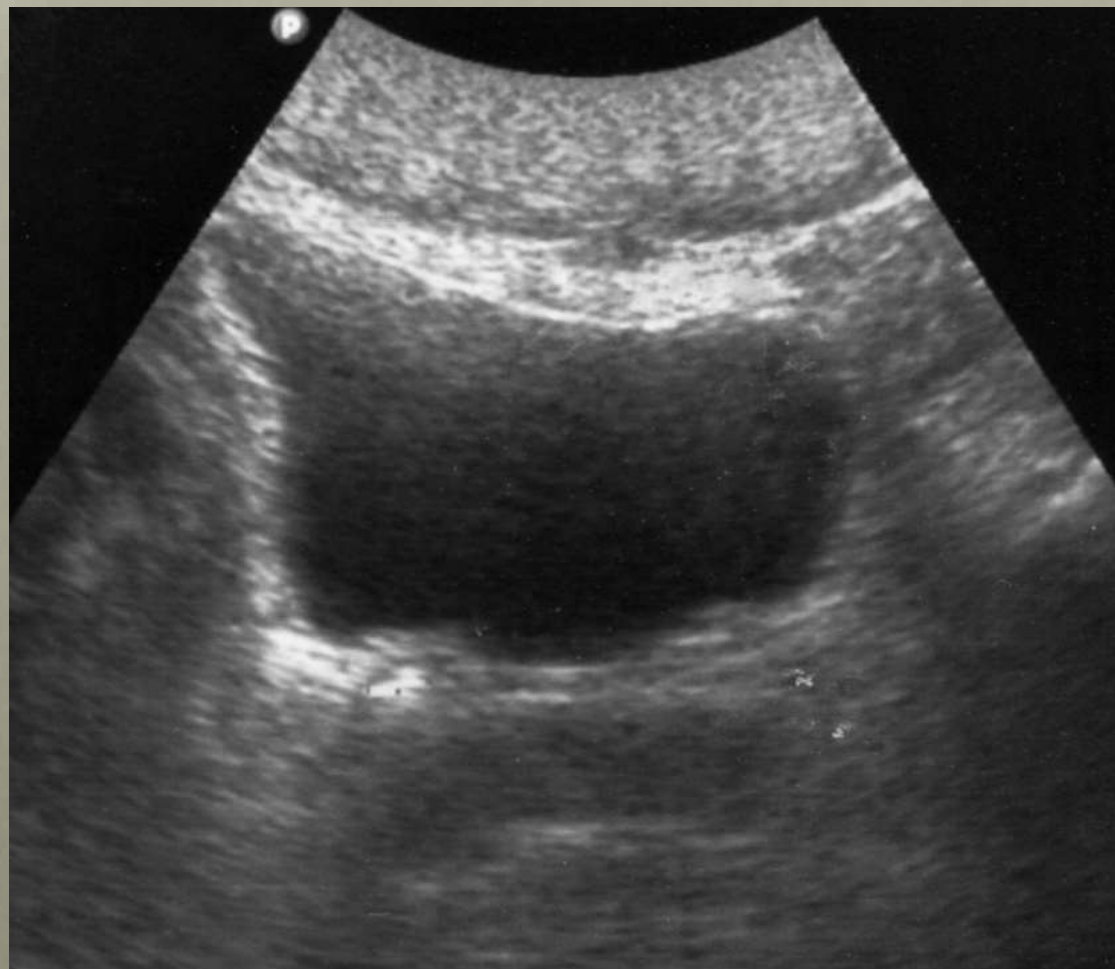A VESE



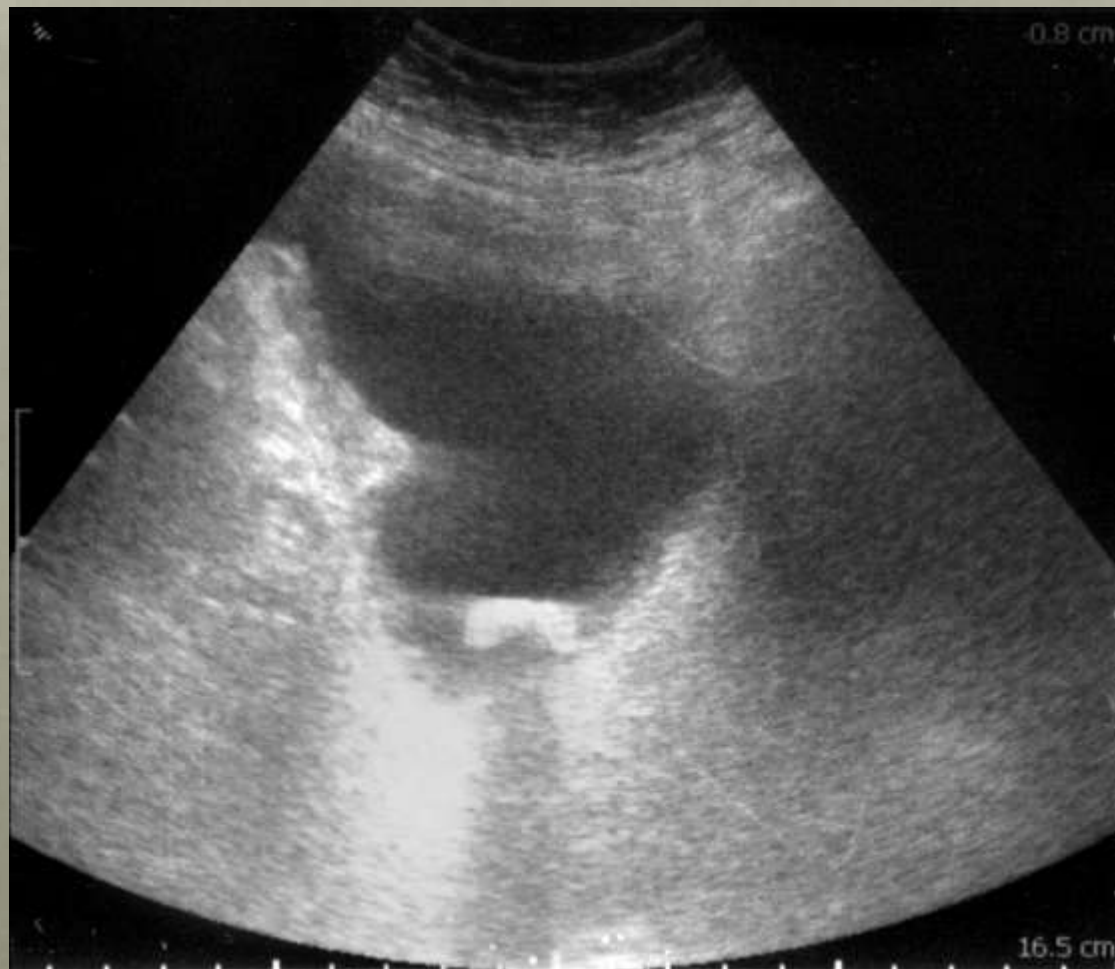A VESE



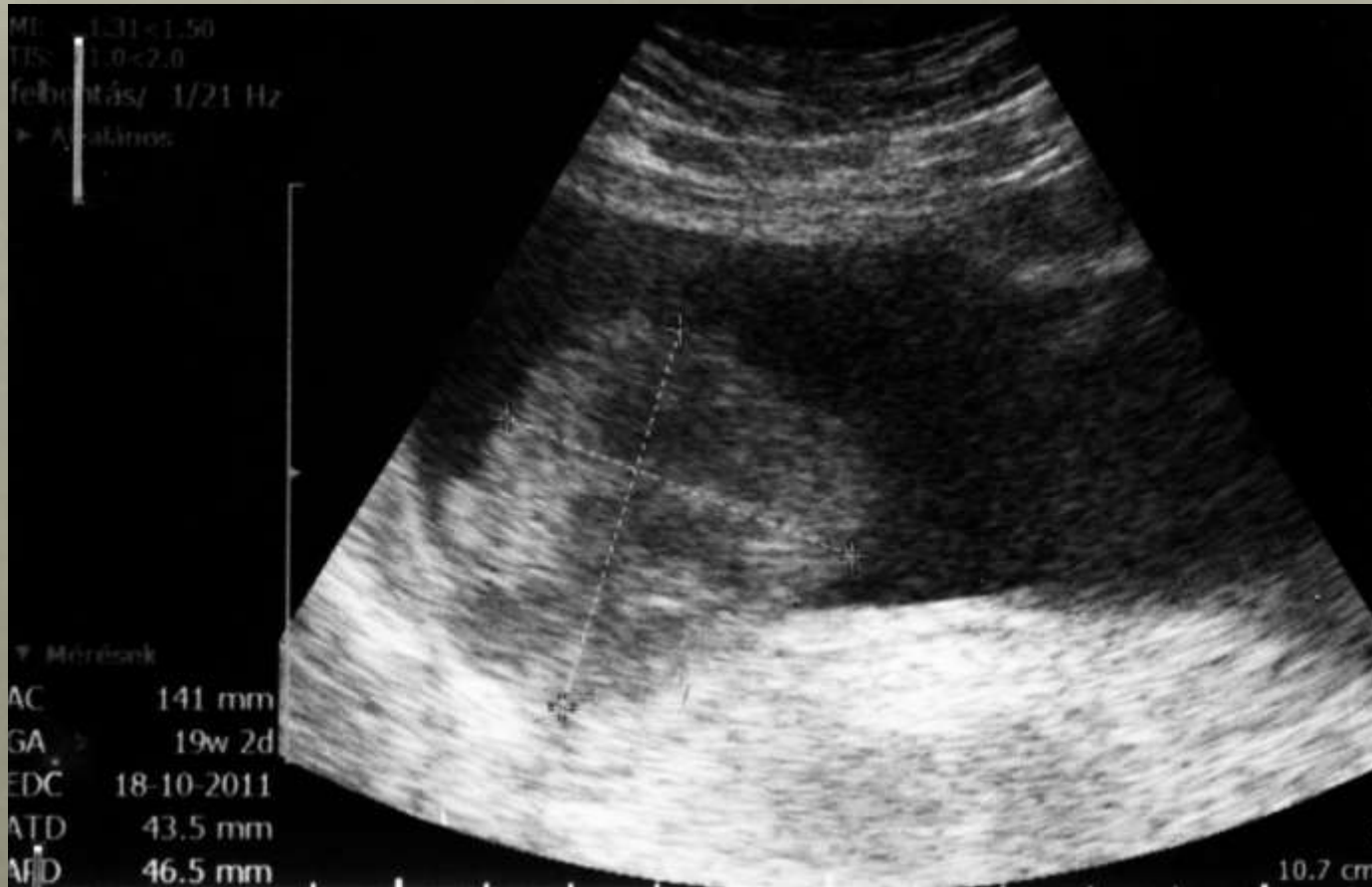
A HÓLYAG



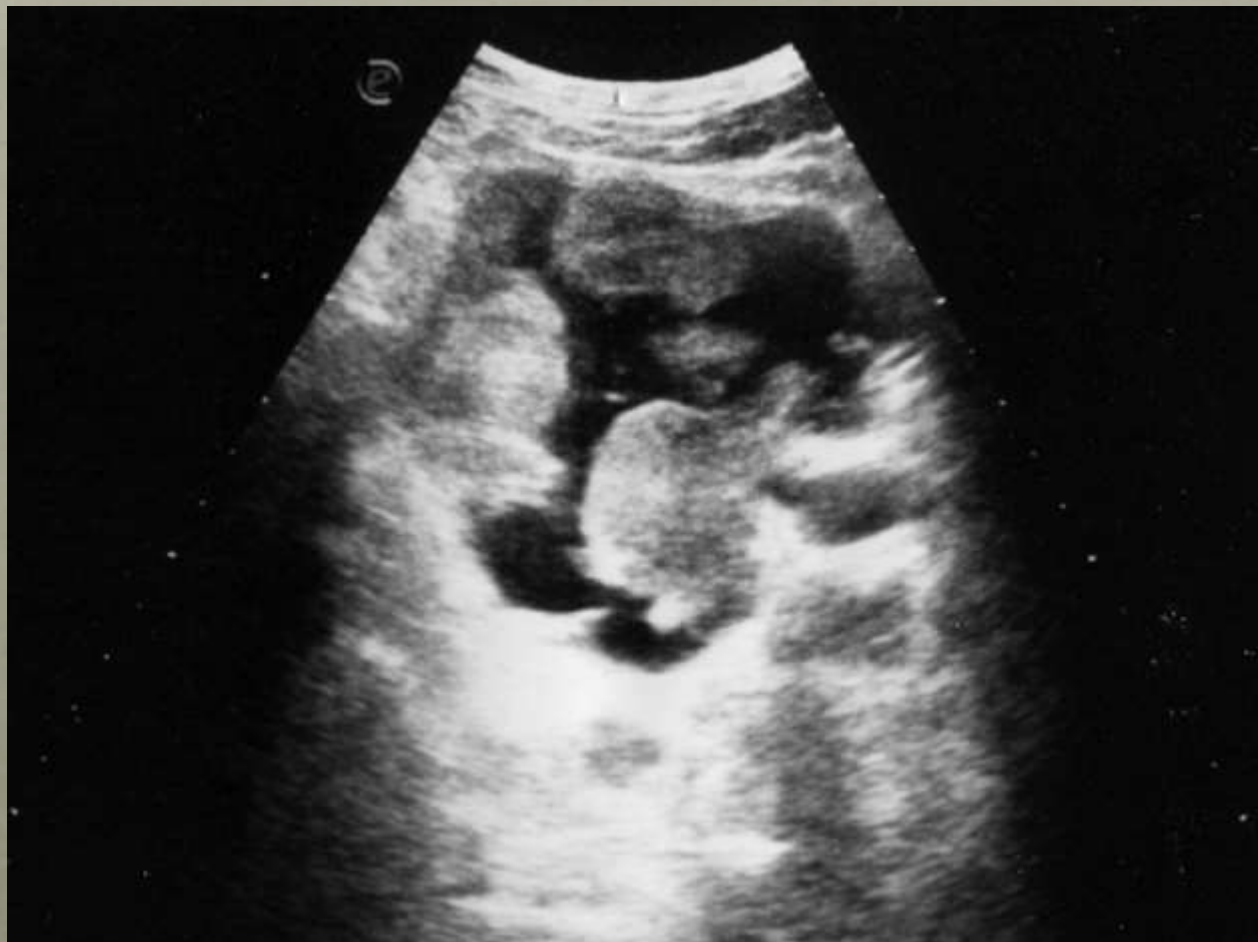A HÓLYAG



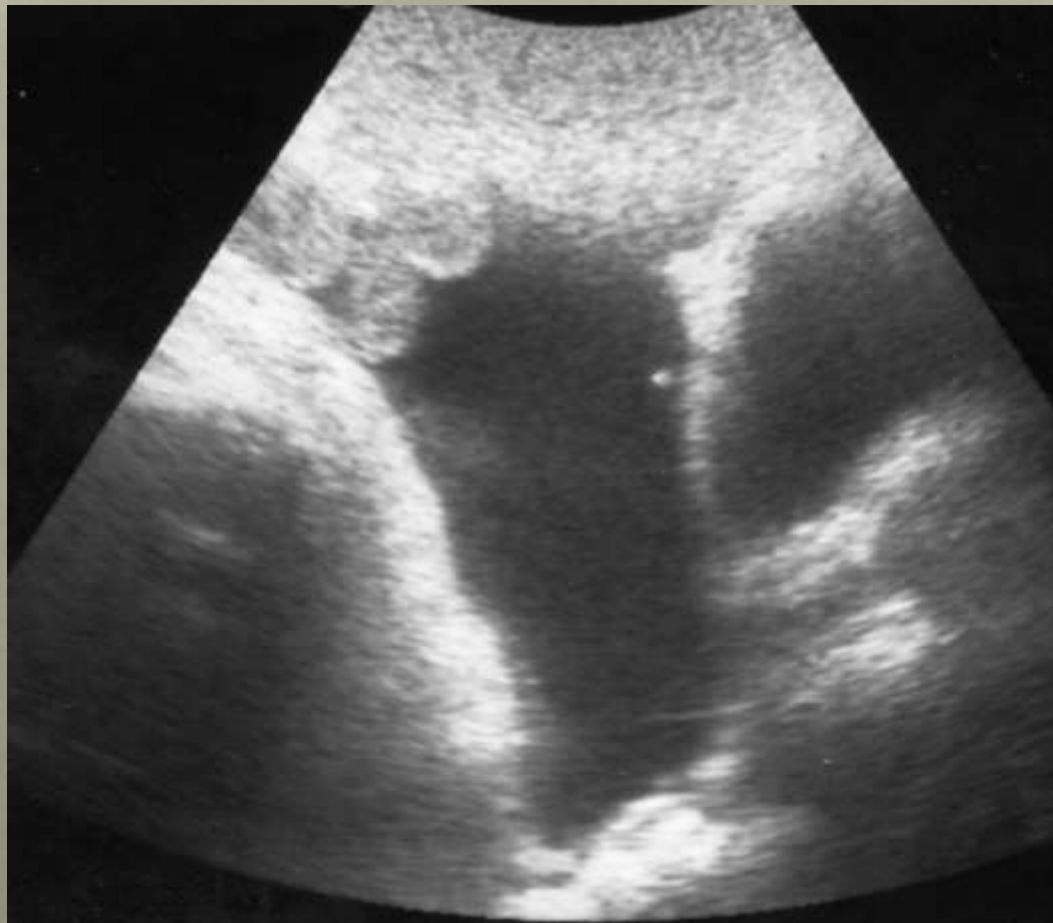A HÓLYAG



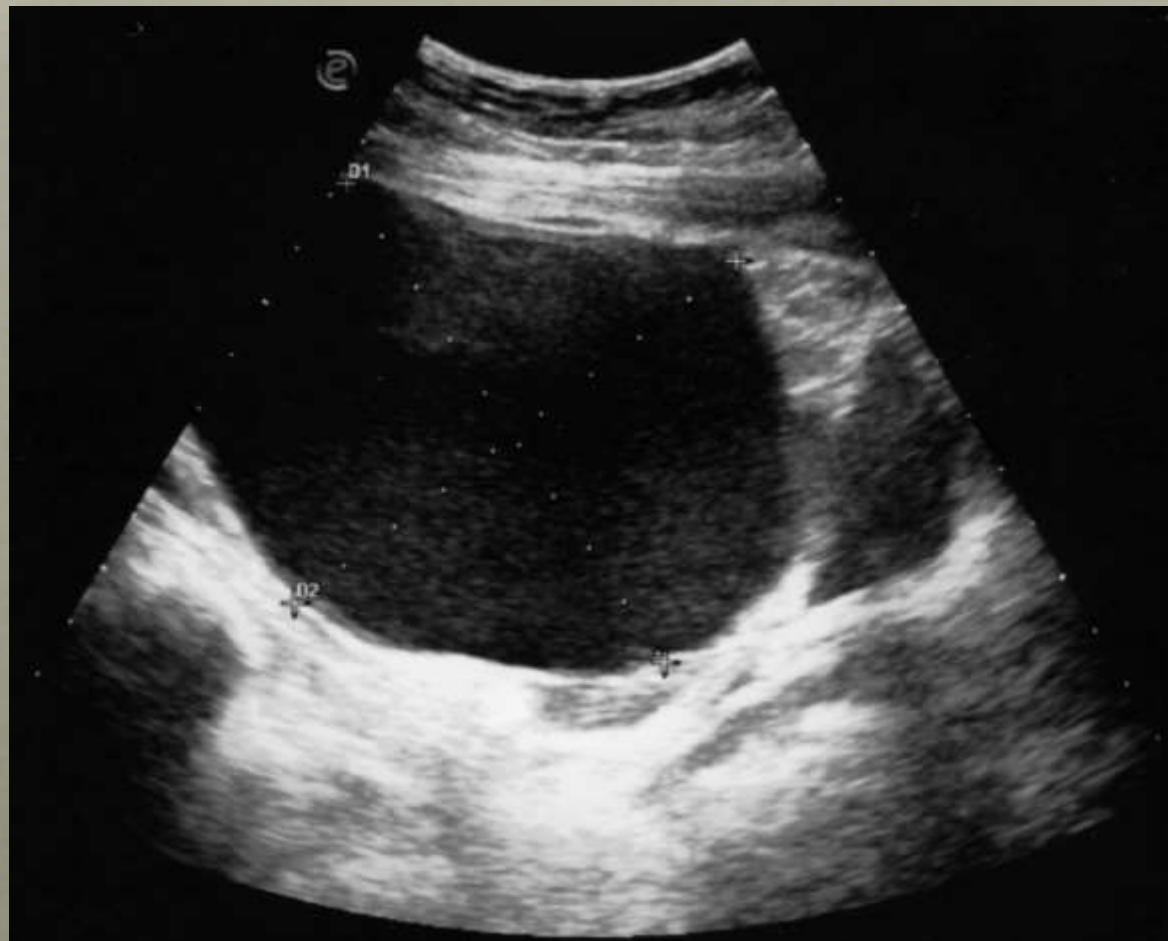A HÓLYAG



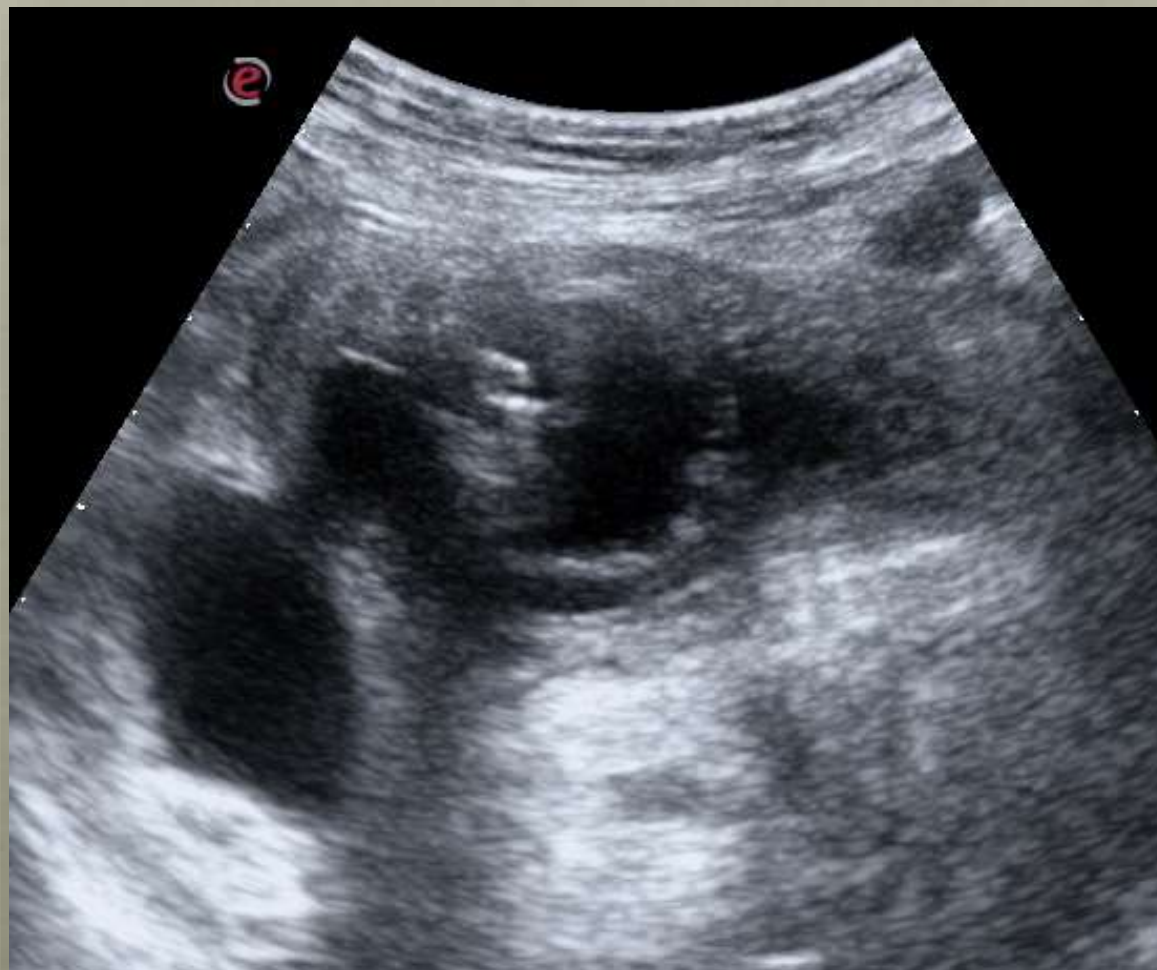A HÓLYAG



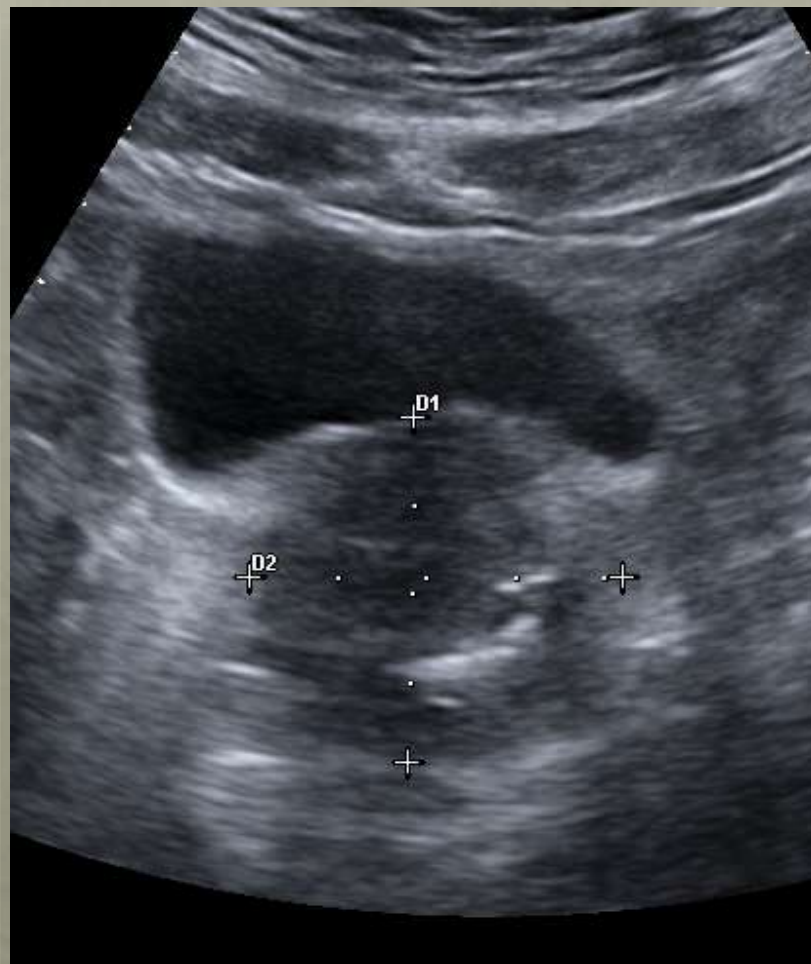A HÓLYAG



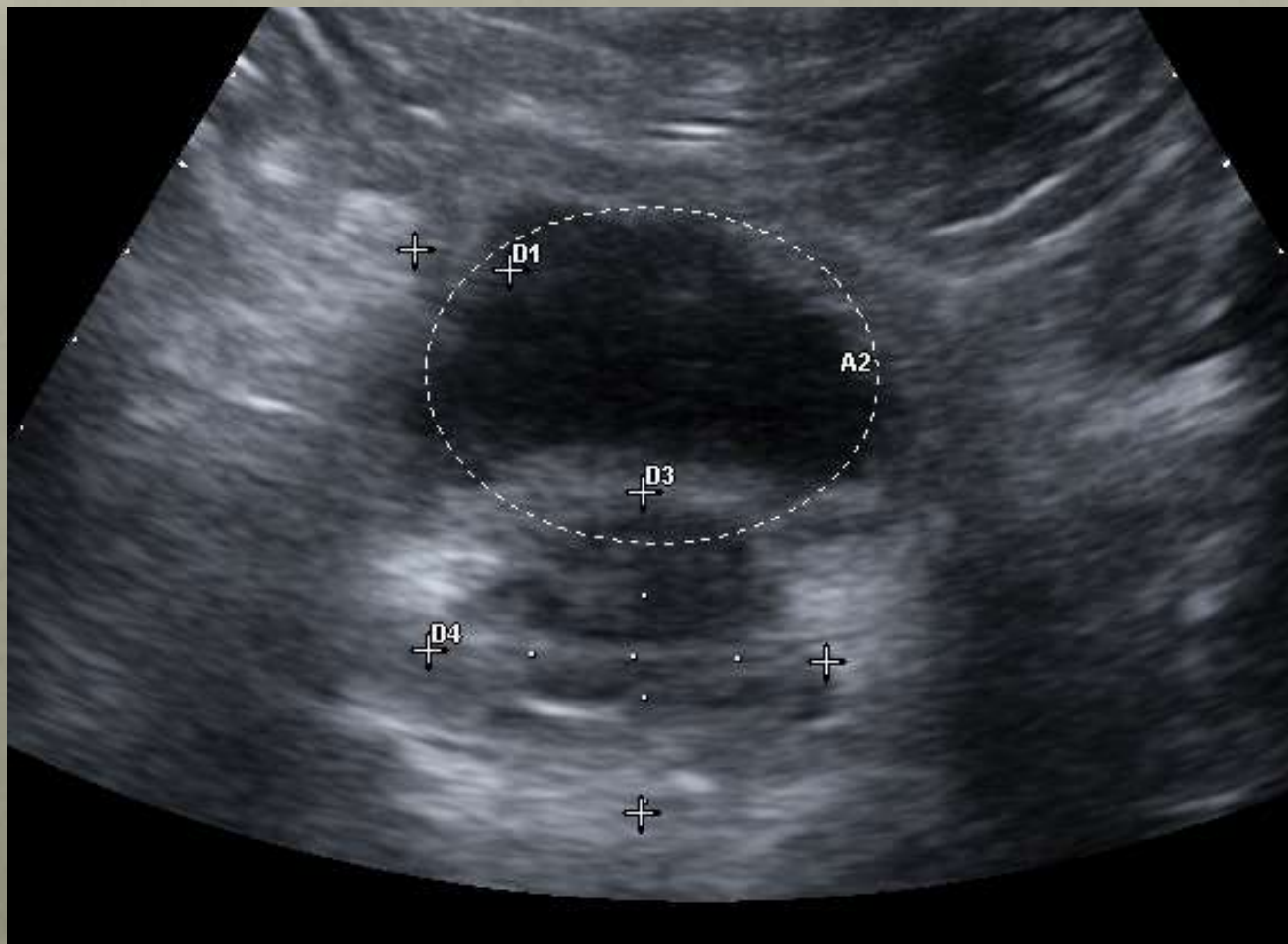
A HÓLYAG



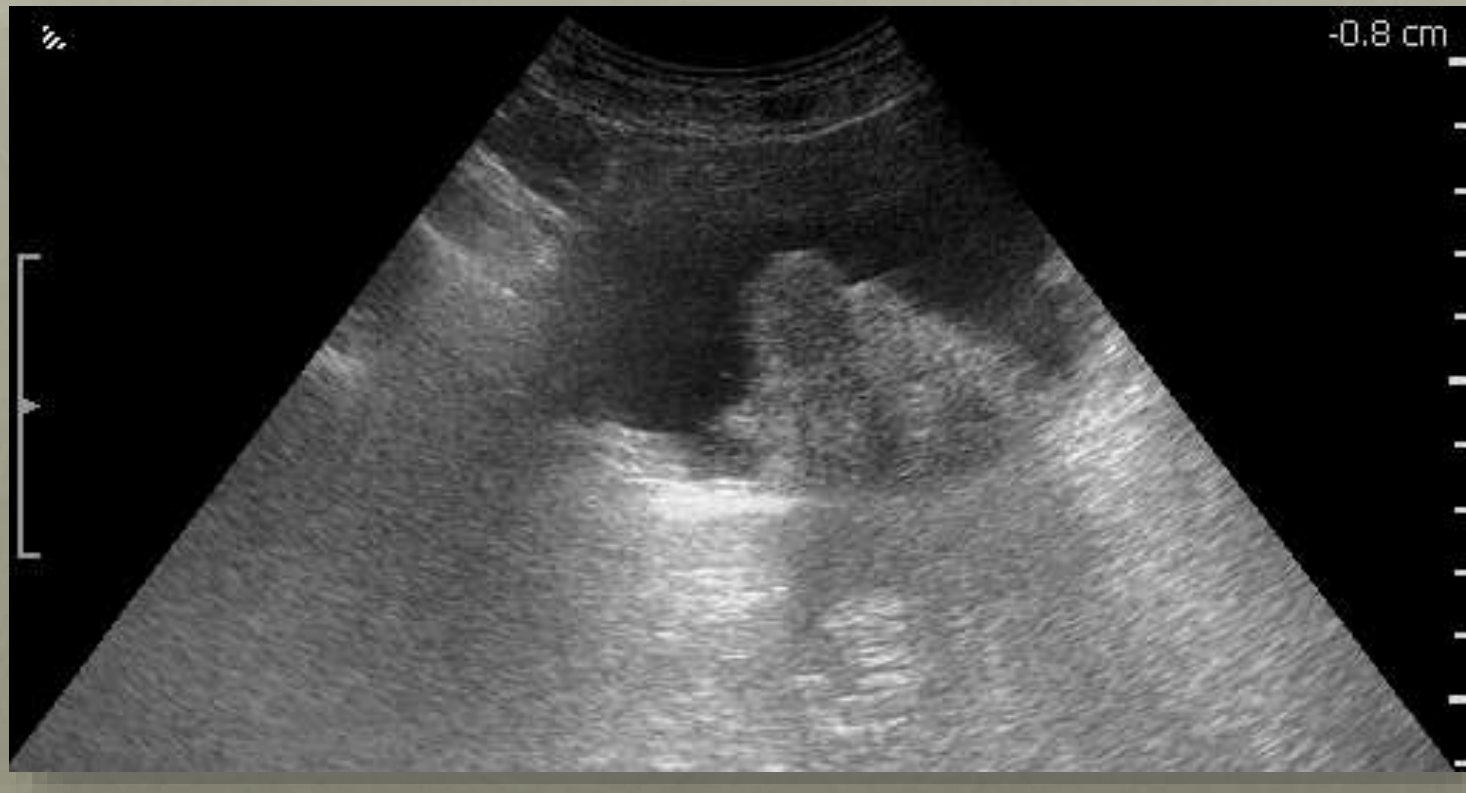A PROSZTATA



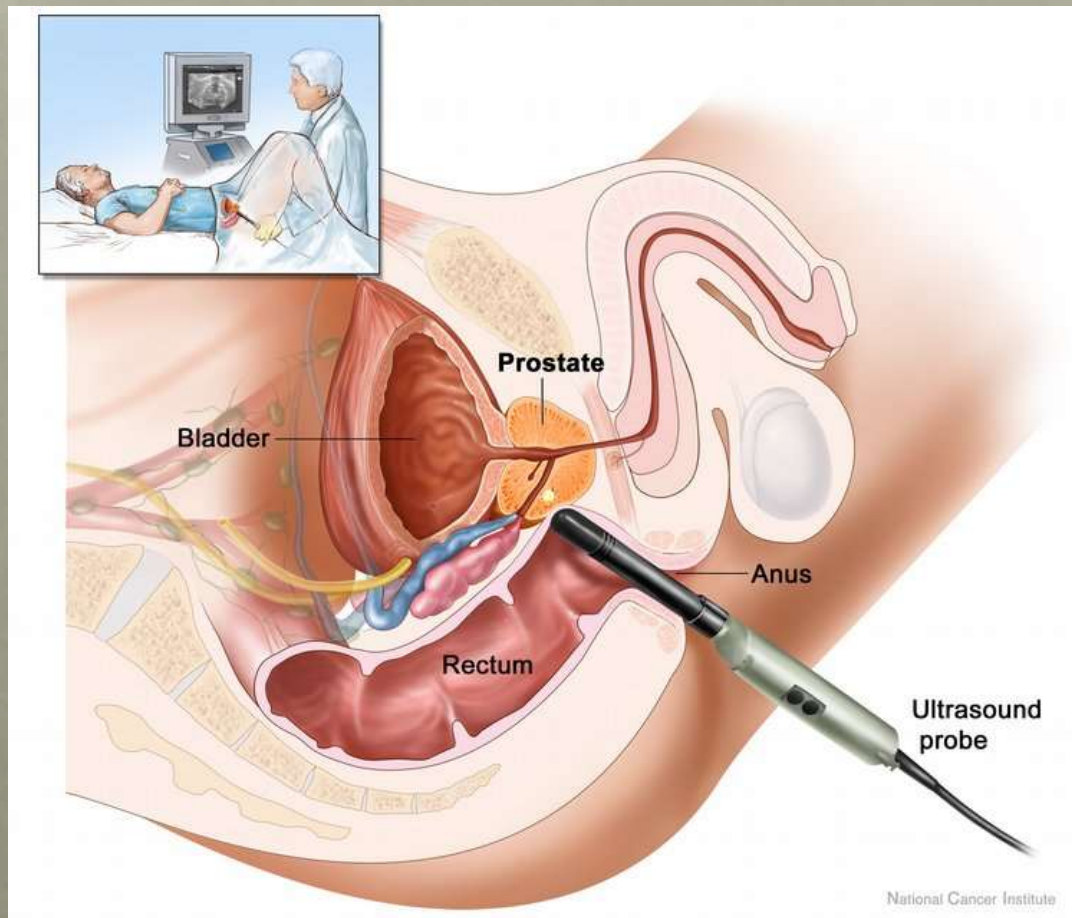
A PROSZTATA



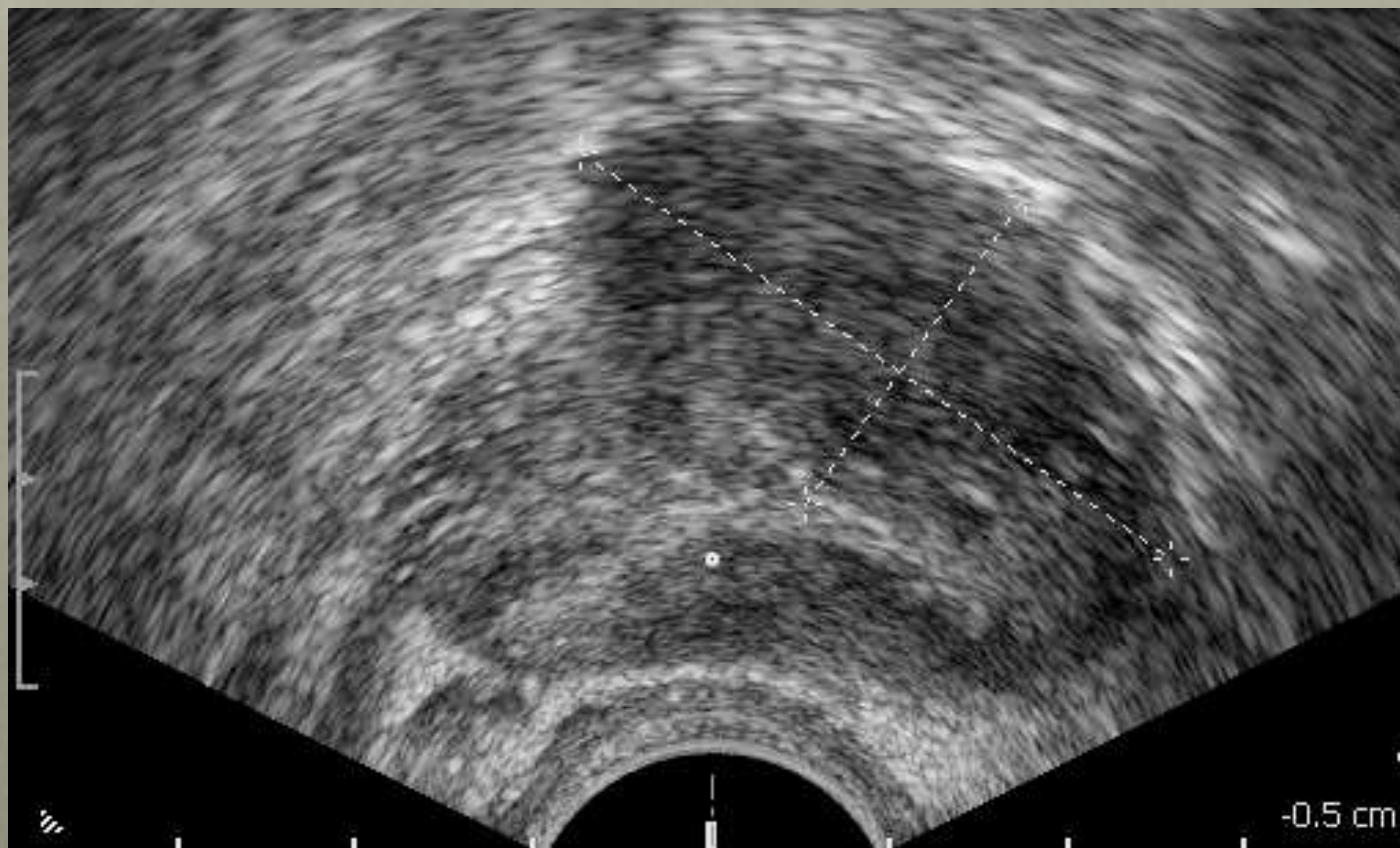A PROSZTATA



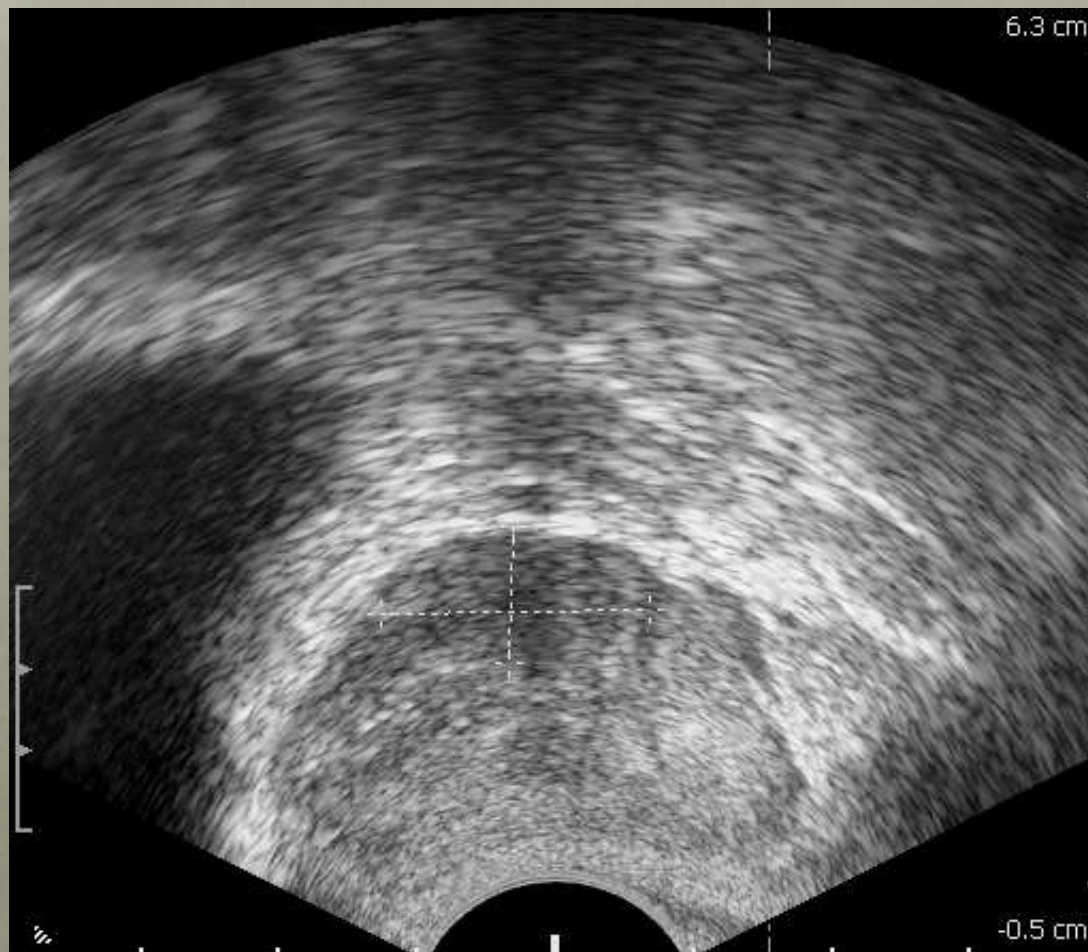A PROSZTATA



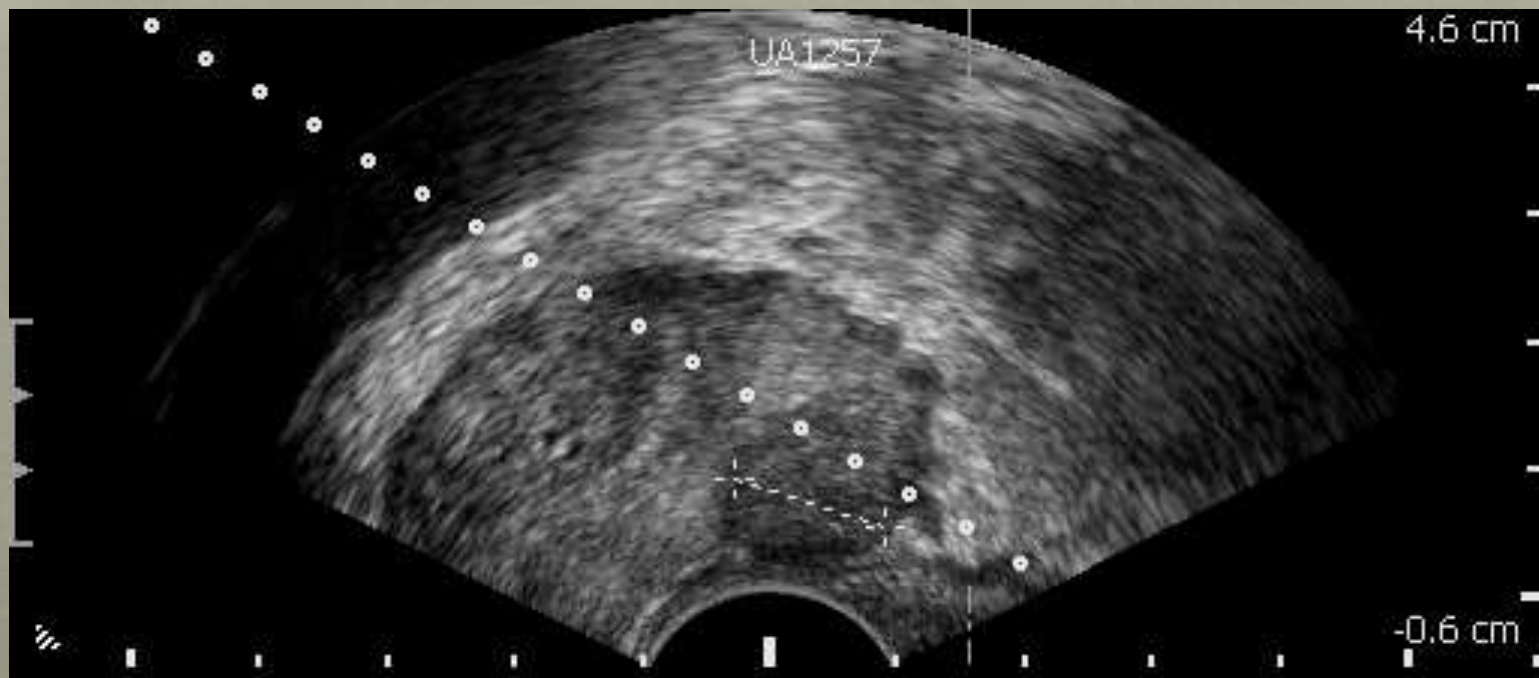
A PROSZTATA



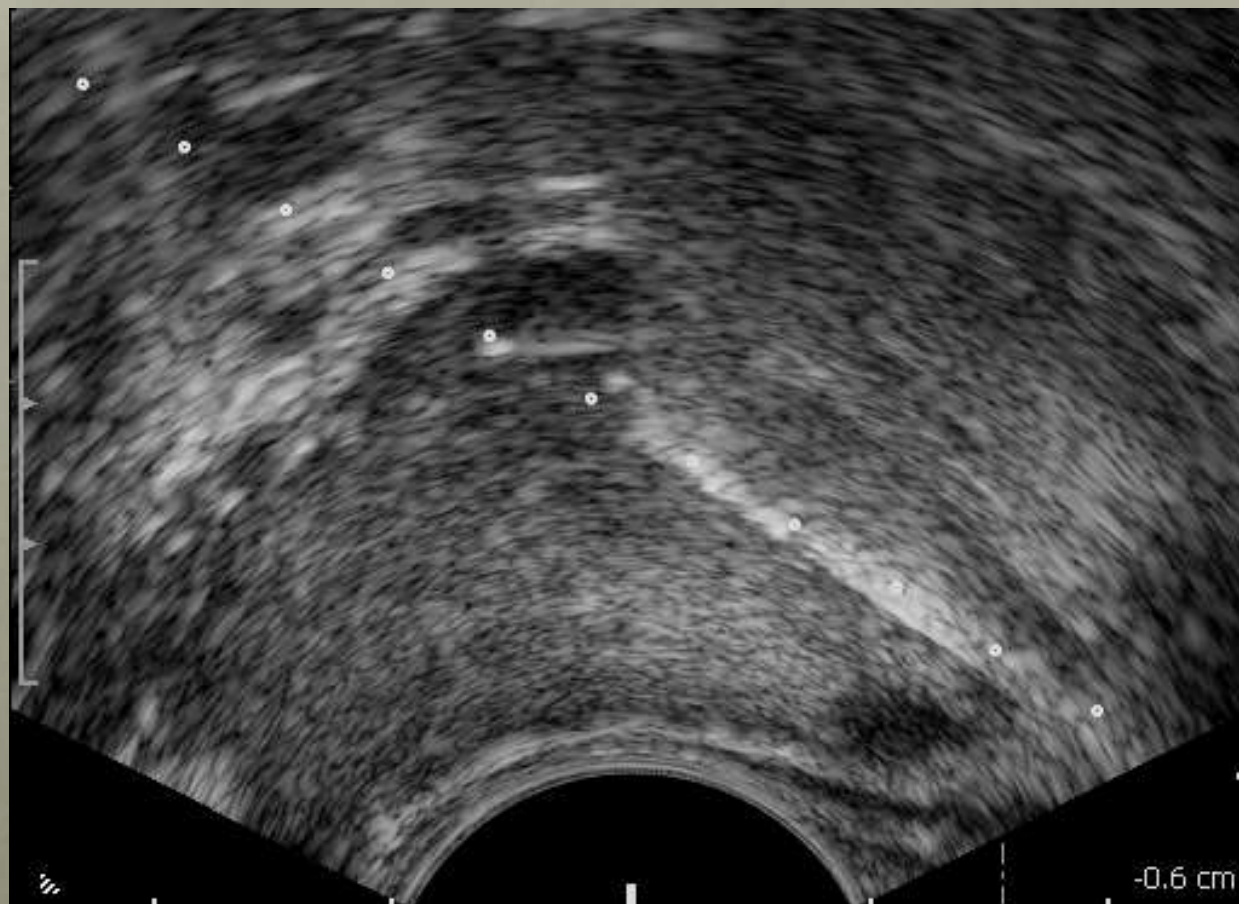
A PROSZTATA



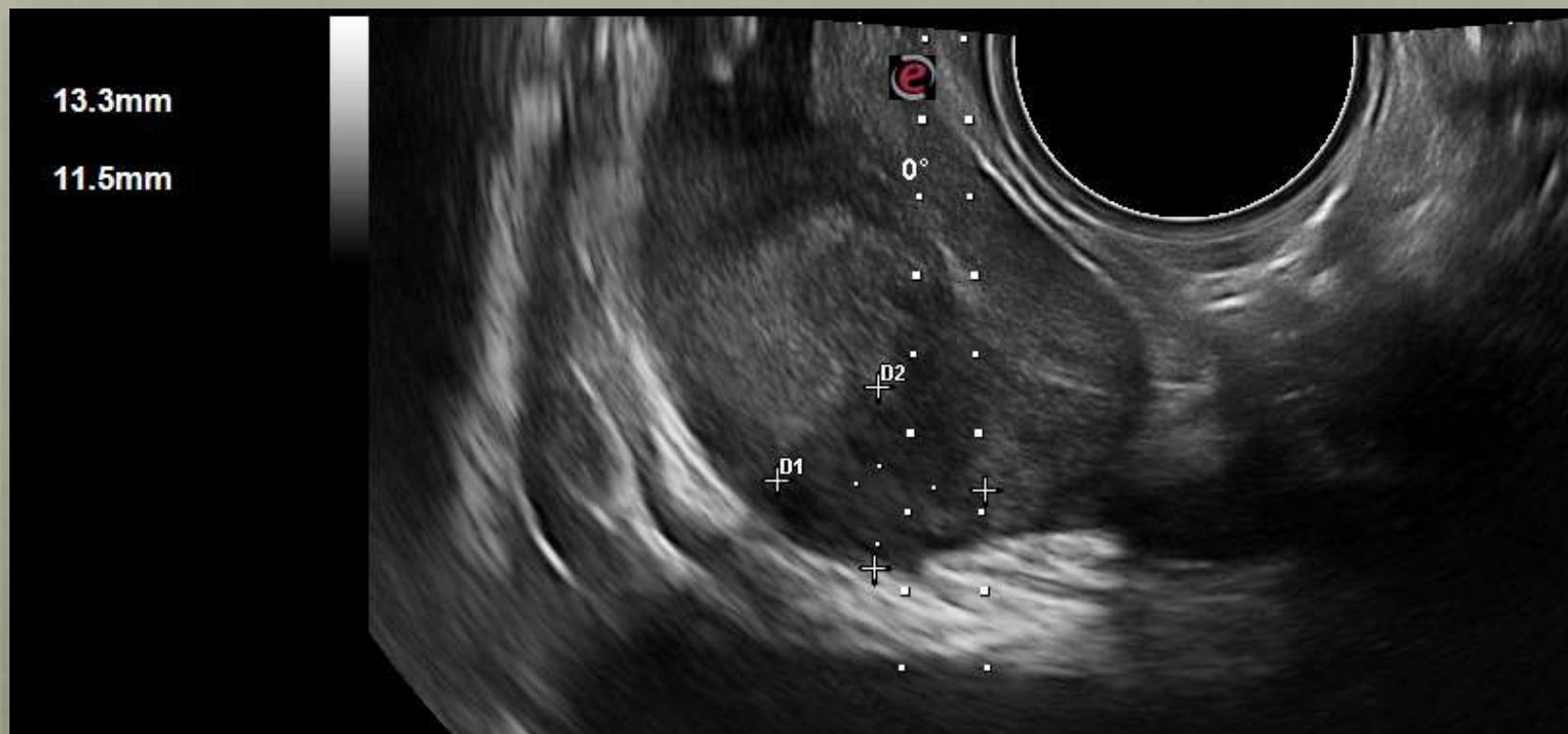
A PROSZTATA



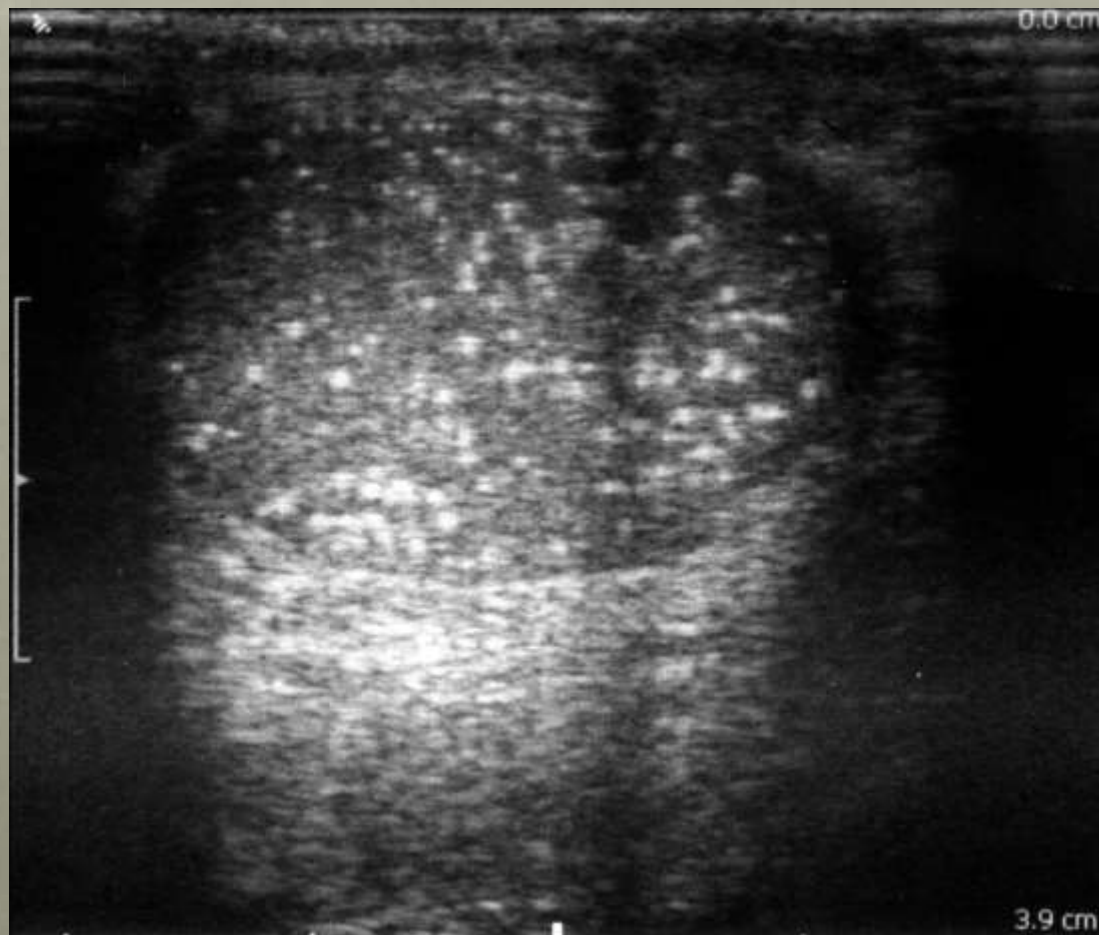
A PROSZTATA



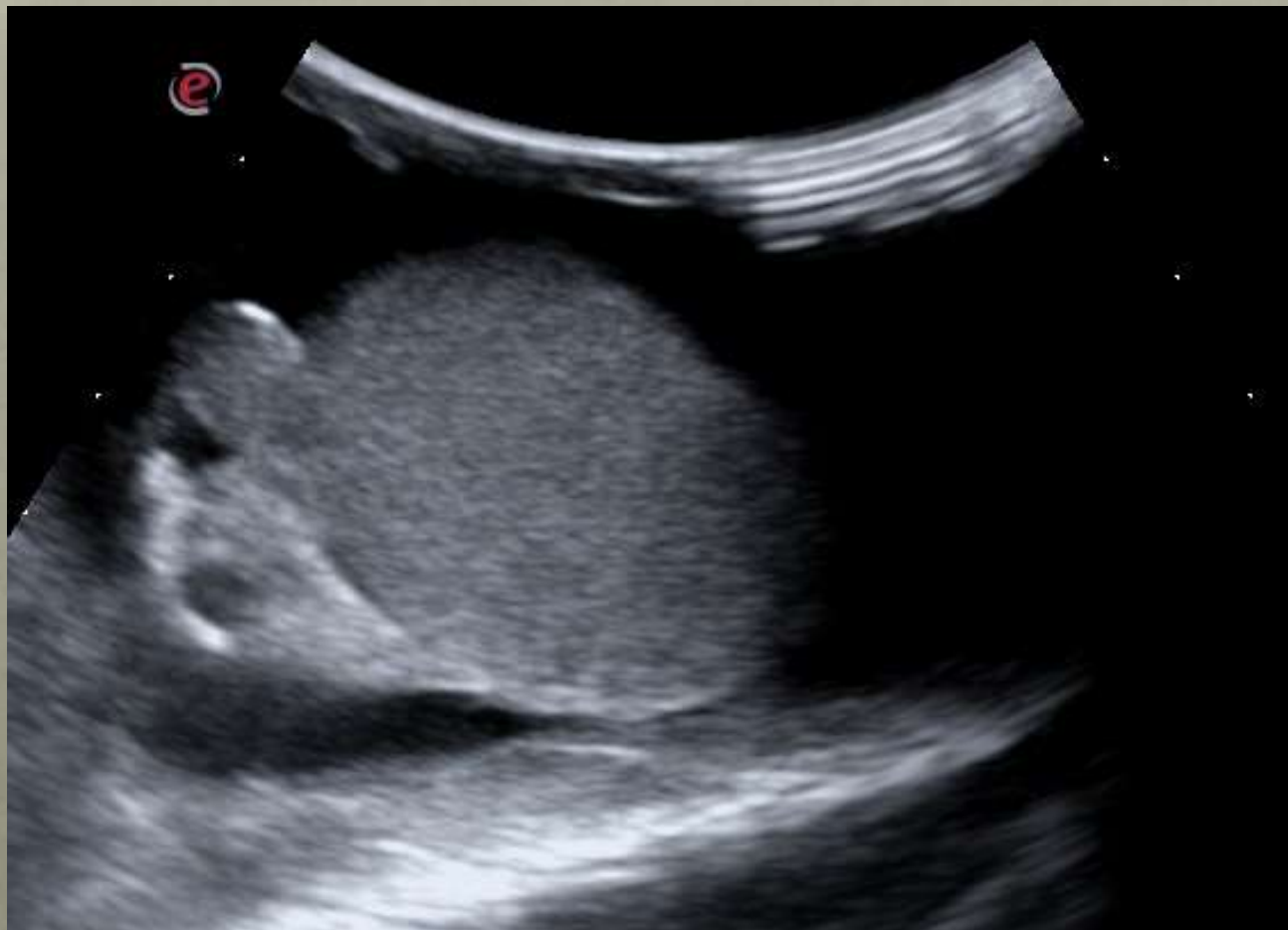A PROSZTATA



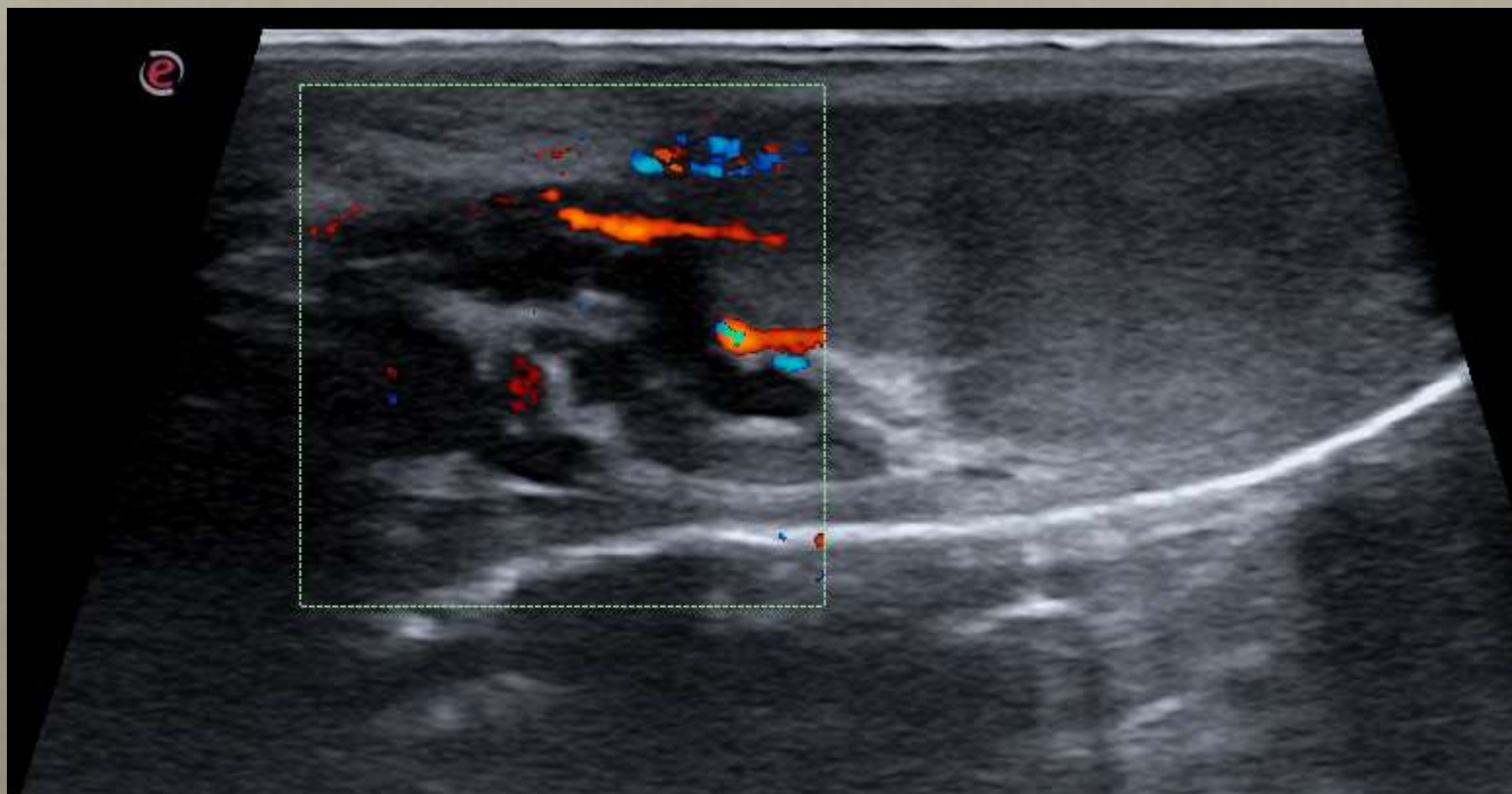
A HERE



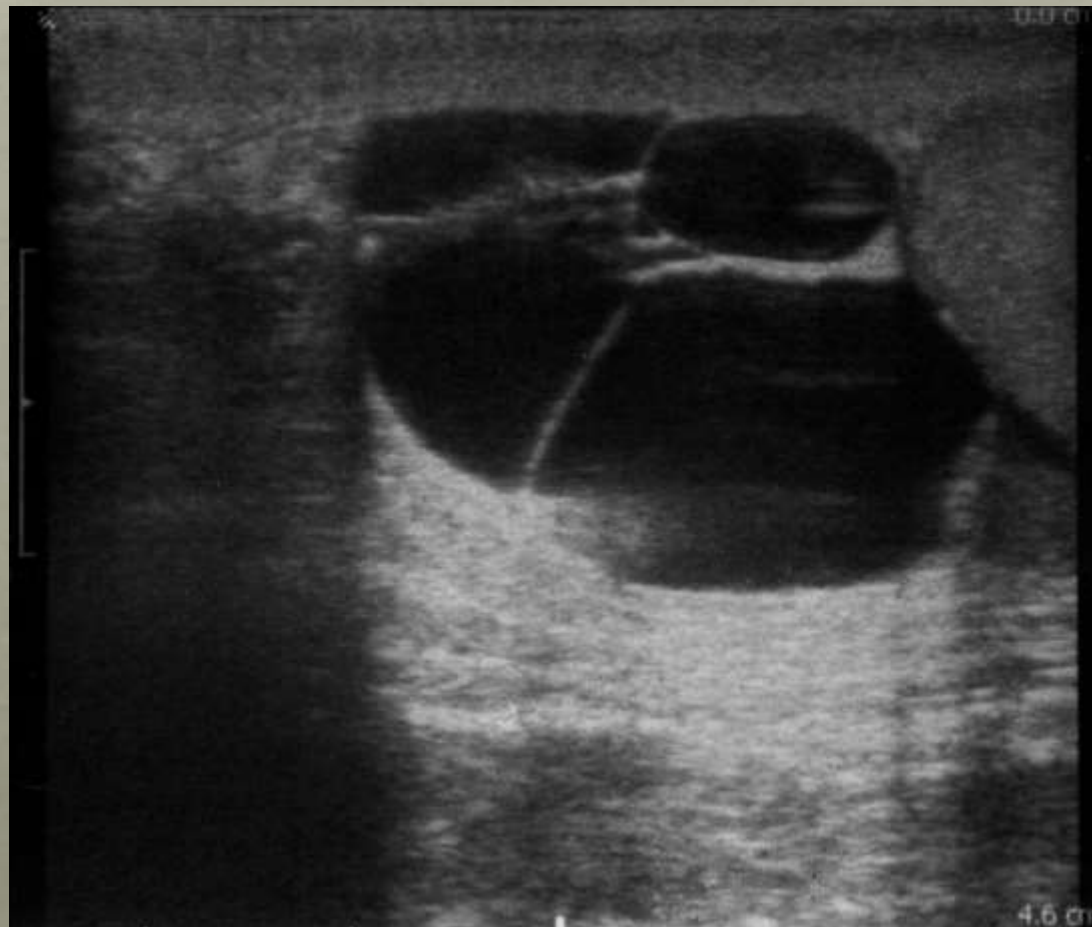
A HERE



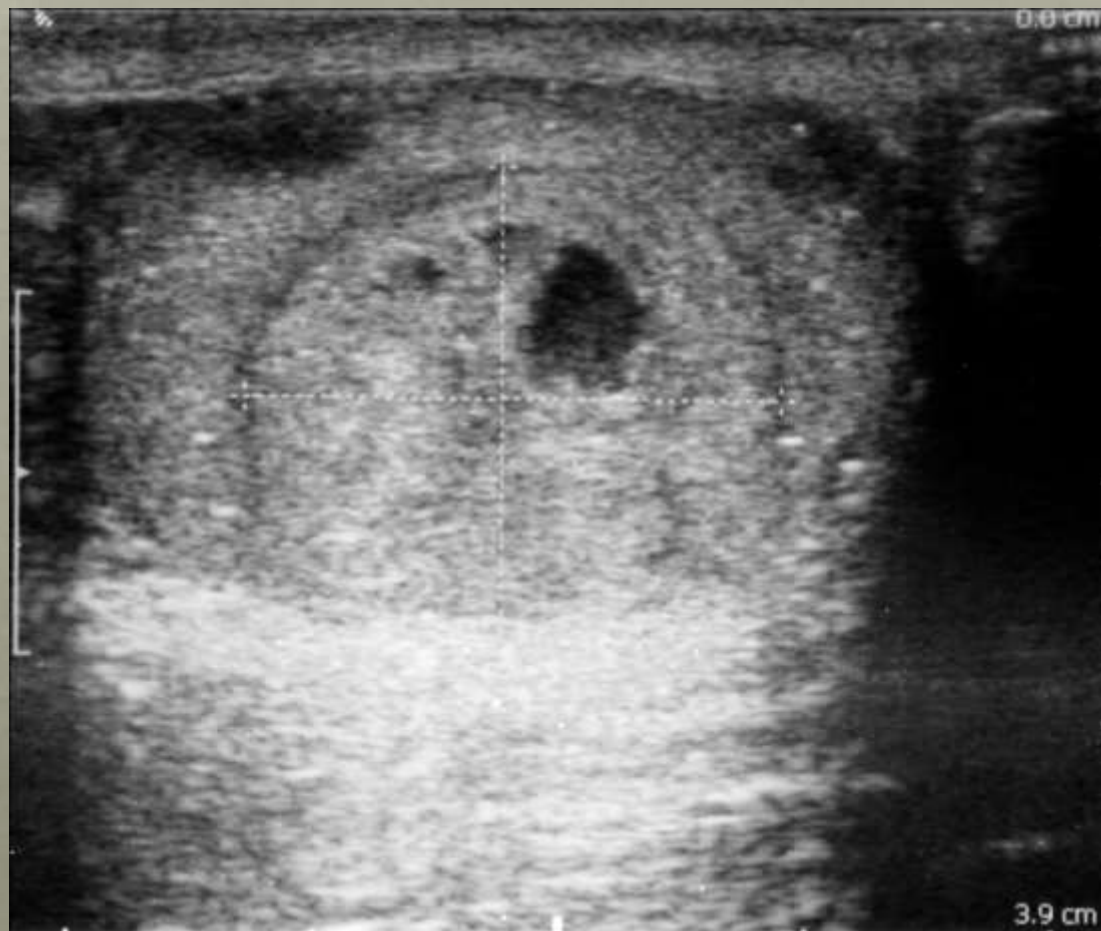
A HERE



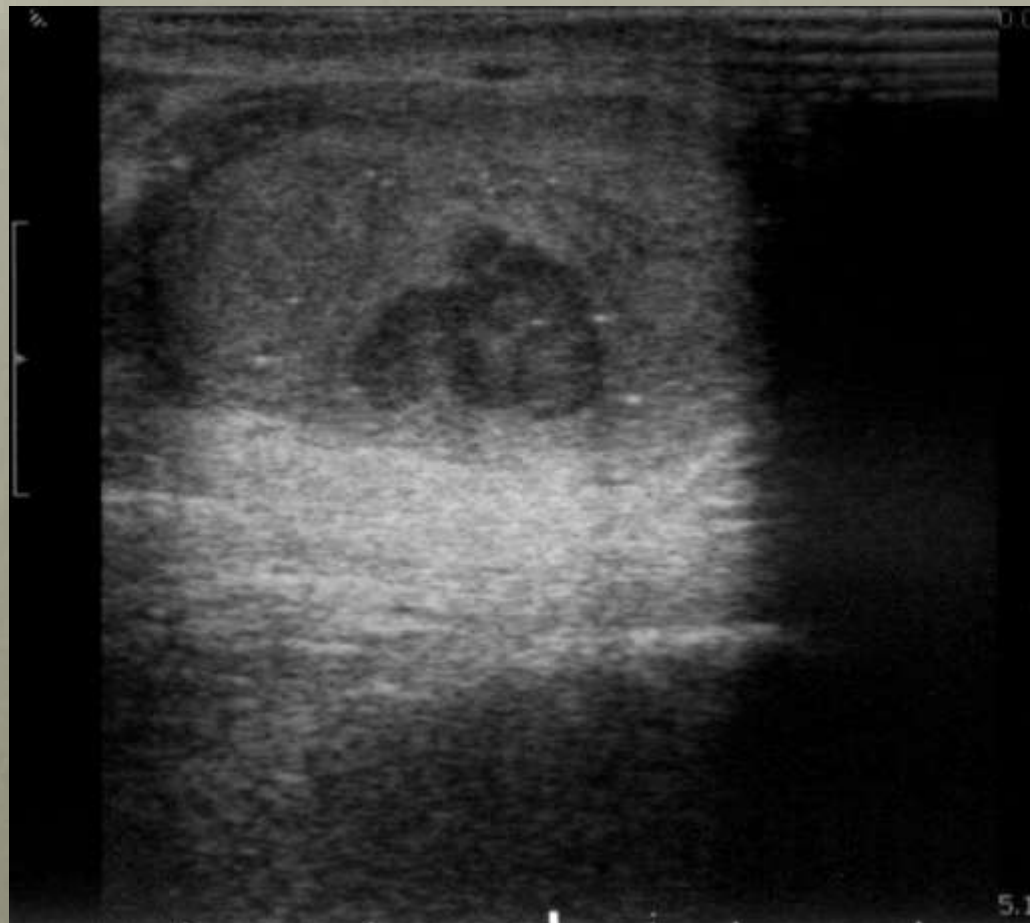
A HERE



A HERE

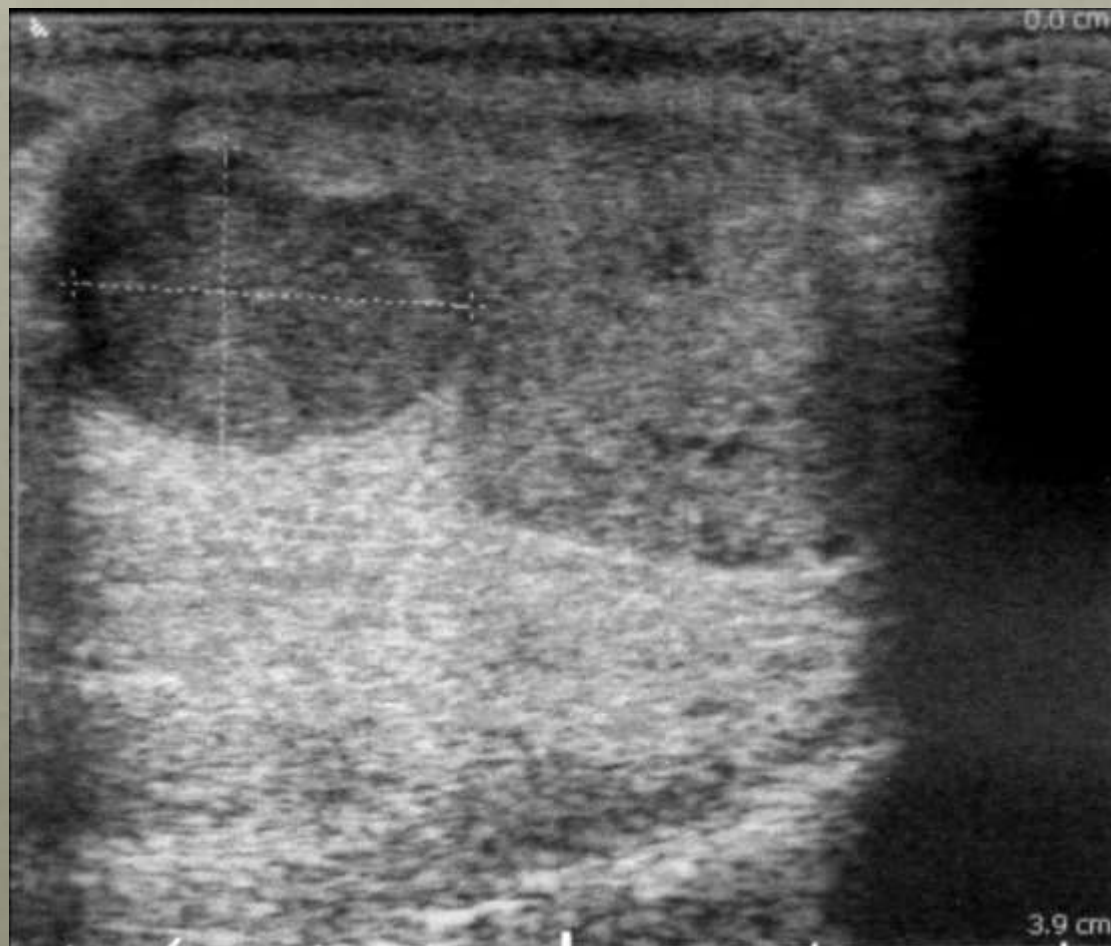


A HERE

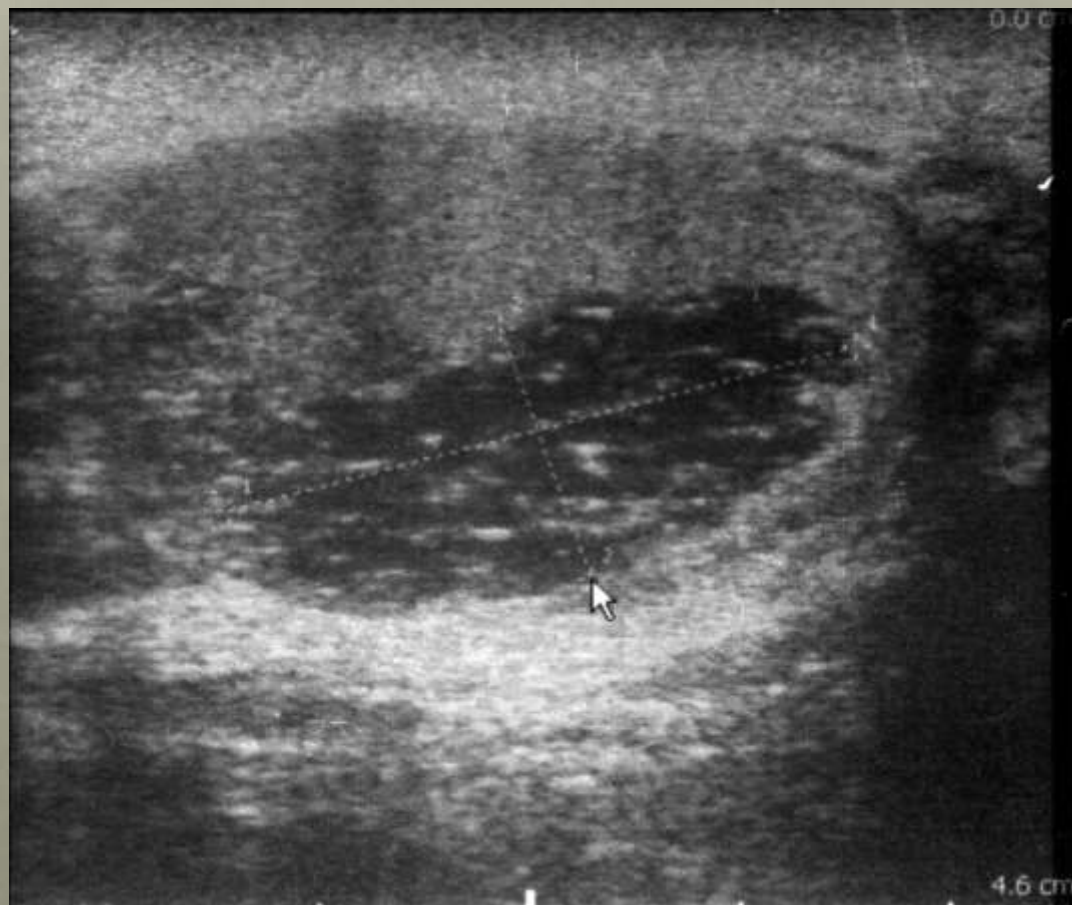


5.1

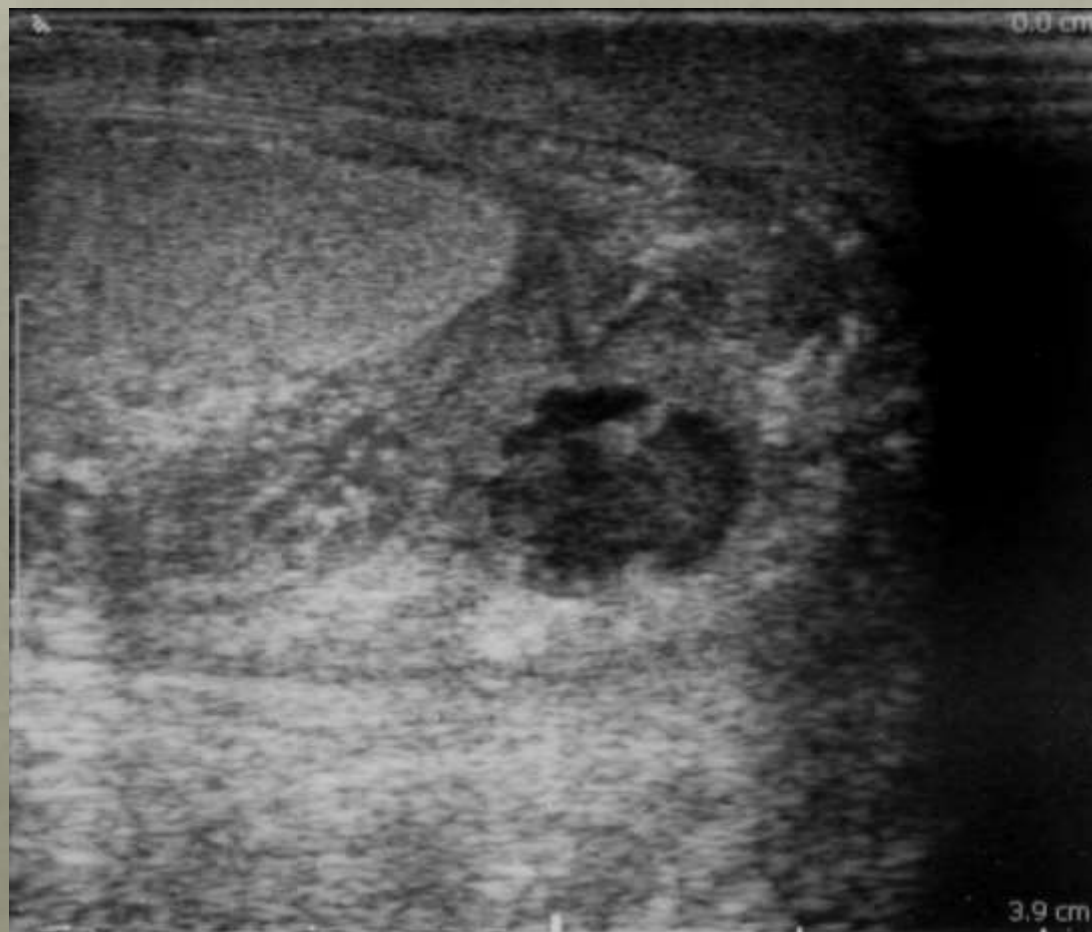A HERE



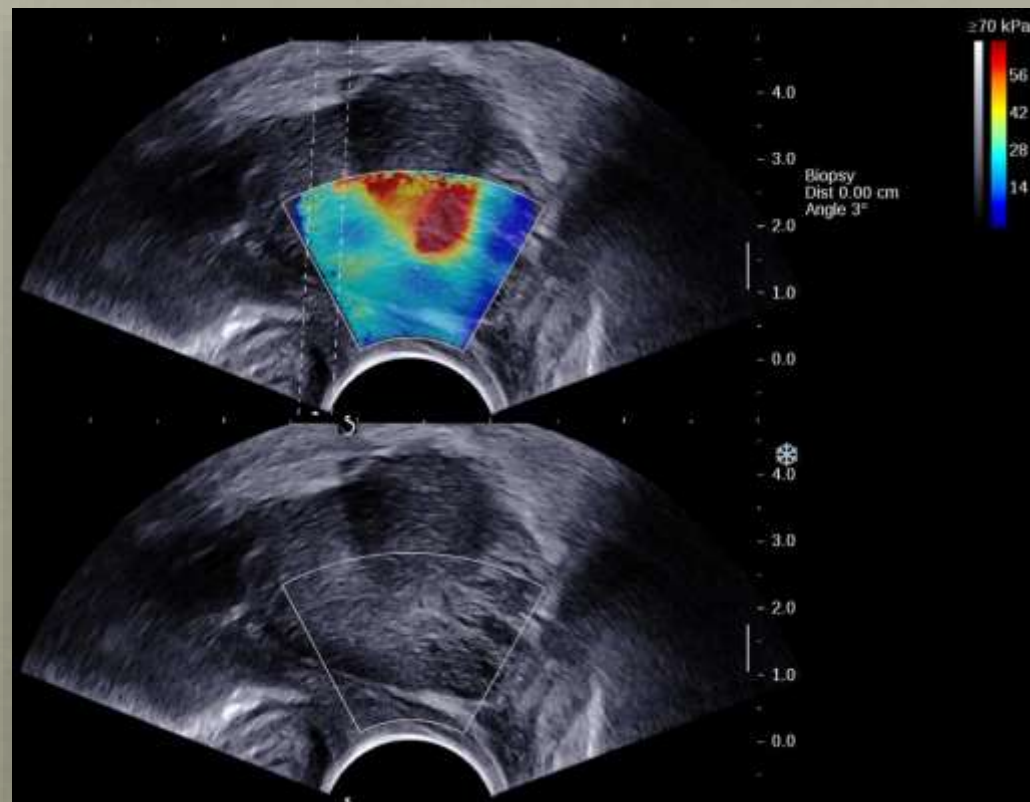
A HERE



A HERE



ELASZTOGRÁFIA





KOSZONOM A FIGYELMET!

Dr. Kocsis Istvan Tamas "Szegedi Uti Akademia 2016"